



## PRESENTING CLINICAL SIGNS

### PATIENT

Ginger Lewis  
History: recheck from last time swelling on back left leg  
Abnormal PE/Chem/CBC/UA Results:

## SPECIES RADIOGRAPHIC STUDY OF THE STIFLES

Canine  
The soft tissue swelling surrounding the joint is similar to the previous study. It may represent effusion, fibrosis or a combination of both. The gastrocnemius tendon is thicker and less well defined than previously.

### BREED

Lab  
One tibio-tarsal joint space is enlarged which is compatible with the increased medial joint space on the previous DP view. The new bone formation appears similar. However, the changes on the caudal aspect of the distal tibial cortex seem to have smoothed off.

### SEX

## RADIOGRAPHIC DIAGNOSIS

Spayed Female

- OCD with OA and peripheral soft tissue swelling as before
- Mild thickening of gastrocnemius tendon

### AGE

## INTERPRETATION OF THE FINDINGS & FURTHER RECOMMENDATIONS

7 Years  
The hock changes appear similar to the previous study. The swelling on the tuber calcis may be due to the marginal increase in joint extension or could represent a tendinopathy. Ultrasound is recommended to assess the tendons at the tuber calcis. Radiographs of the other tarsus should be obtained, if it has not already been done, because OCD can occur bilaterally.

## INTERPRETED BY

Heike Rudorf, DVM,  
Dr. med. Vet.,  
DipECVDI DVR

## HOSPITAL NAME

Rockaway AH

## REFERRING VET

Dr. Maniar

## INVOICE

13986

## DATE

10/22/21

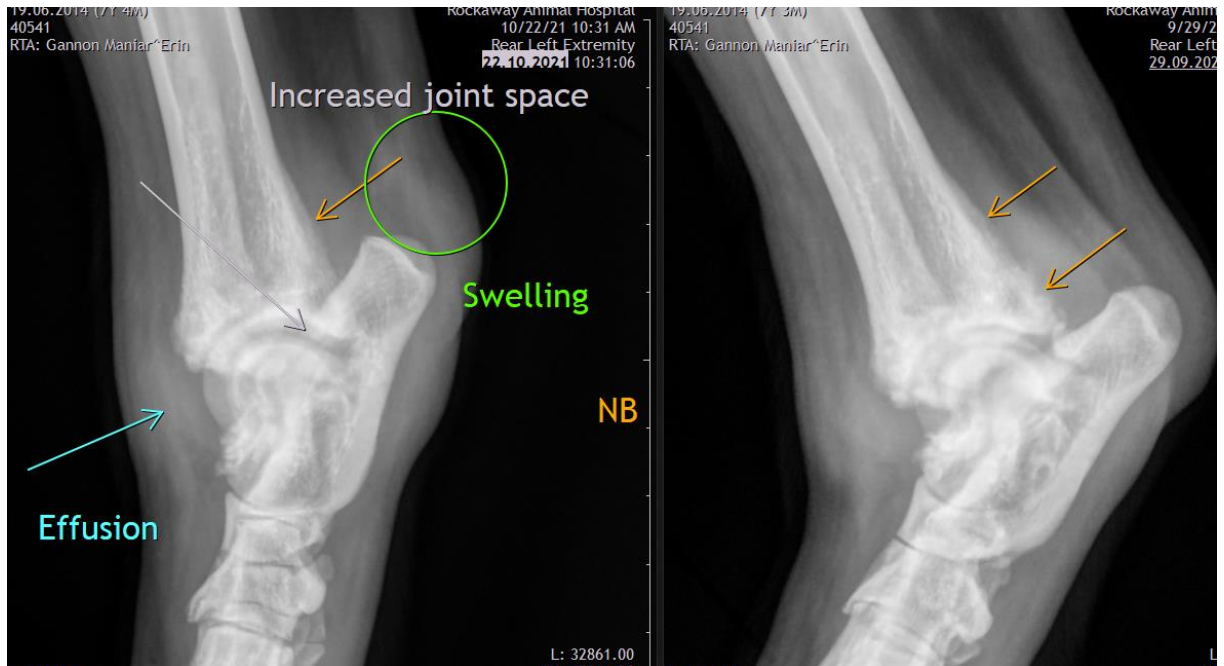


**PATIENT**  
Ginger Lewis

**SPECIES**  
Canine

**BREED**  
Lab

**SEX**  
Spayed Female



**AGE**  
7 Years

The information and recommendations provided are based on the images presented by the referring veterinarian. No evaluation can be communicated regarding pathology that was not visible in the image/video clips provided.

Thank you for this referral. If the clinical or image interpretation does not parallel your findings or if I can be of any further assistance please contact me.

**INTERPRETED BY**  
Heike Rudorf, DVM,  
Dr. med. Vet.,  
DipECVDI DVR

**Heike Rudorf, DVM, Dr. med. vet., DipECVDI, DVR**  
dr.h.rudorf@gmail.com

**HOSPITAL NAME**  
Rockaway AH

**REFERRING VET**  
Dr. Maniar

**INVOICE**  
13986

**DATE**  
10/22/21