



PATIENT PRESENTING CLINICAL SIGNS

Ario Leber History: Acute onset of non-productive coughing and gagging. Consumed a lamb bone a few days prior to this onset. was at the dog park but all the dogs are not showing any symptoms. PE - no significant findings, except he gained 1 kg since February 2020

SPECIES Abnormal PE/Chem/CBC/UA Results:

Canine RADIOGRAPHIC STUDY OF THE THORAX

BREED The body condition score is 7-8/9 with smooth alternating layers of fat and soft tissue opacity. Rib 13 is missing on the left.

Pug Cross The degree of pulmonary expansion is fair at best. The outline of the lobar vessels is blurred, and bronchi are highlighted.

SEX The cranial mediastinum is of physiological size and opacity. The tracheal lumen is reduced from dorsally between C3 and T1 by a crescent shaped, soft tissue opacity.
Neutered Male

AGE The cardiac silhouette occupies 85% of the chest height and 3 intercostal spaces (VHS 11). The caudal heart border is straight, and the left atrium is slightly prominent.

8 Years RADIOGRAPHIC DIAGNOSIS

- Tracheal collapse
- Interstitial pattern
- Possible mild left atrial enlargement

INTERPRETED BY

Heike Rudolf, DVM,
Dr. med. Vet.,
DipECVDI DVR

INTERPRETATION OF THE FINDINGS & FURTHER RECOMMENDATIONS

HOSPITAL NAME

Sunridge VC

Tracheal collapse alone can be due to a weakened dorsal tracheal ligament. Tracheal in combination with bronchial collapse is usually caused by chondromalacia and is thus due to an altered cartilage development which may go unnoticed until physical circumstances (such as stress, running, excitement) or disease (e.g., pneumonia, bronchitis, L cardiac enlargement) reduces the ease of airflow. Echocardiography to assess mitral valve and L atrial size is recommended.

REFERRING VET

Dr. Barry Magill

The generalized interstitial lung pattern is a non-specific finding and accentuated by the only fair expansion of the lung field. Possible differential diagnoses for a true infiltrate include:

- Infection (bacterial, fungal e.g., candida, viral, Rickettsia, Spirochetes, parasitic)
- Inflammation (allergic e.g., eosinophilic bronchopneumonia and PIE, smoke inhalation)
- Edema
- Fibrosis

INVOICE

13995

Further evaluation by means of tracheobronchoscopy with bronchoalveolar lavage should be considered. Should an underlying disease be present treatment may improve the clinical signs.

DATE

10/22/21



PATIENT

Obesity is known to worsen clinical signs of cough and impair lung function; weight control is recommended.

Ario Leber

SPECIES

Canine

BREED

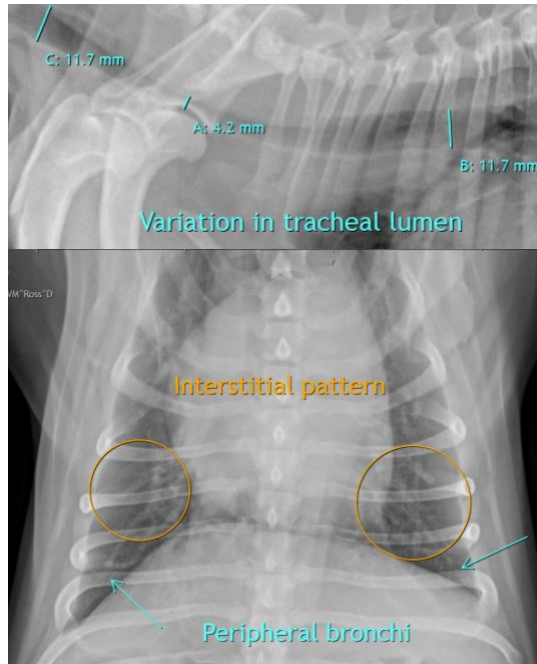
Pug Cross

SEX

Neutered Male

AGE

8 Years



INTERPRETED BY

The information and recommendations provided are based on the images presented by the referring veterinarian. No evaluation can be communicated regarding pathology that was not visible in the image/video clips provided.

Heike Rudorf, DVM,
Dr. med. Vet.,
DipECVDDI DVR

Thank you for this referral. If the clinical or image interpretation does not parallel your findings or if I can be of any further assistance please contact me.

HOSPITAL NAME

Sunridge VC

Heike Rudorf, DVM, Dr. med. vet., DipECVDDI, DVR
dr.h.rudorf@gmail.com

REFERRING VET

Dr. Barry Magill

INVOICE

13995

DATE

10/22/21