



PATIENT PRESENTING CLINICAL SIGNS

Midnight McCarthy History: Swollen mandible L with suspect mandibular canine tooth R/O neoplasia vs dental infection foul odor.

SPECIES Abnormal PE/Chem/CBC/UA Results: Pending

Feline

RADIOGRAPHIC STUDY OF THE HEAD

BREED

Both mandibular rami are almost completely superimposed onto one another. The bony structure of the rostral 2.5cm of the mandible is slightly disorganized and a clear differentiation between medulla and cortex is not possible. A mild soft tissue swelling surrounds this region. A lucent halo around the canine tooth roots is not immediately obvious.

DSH

RADIOGRAPHIC DIAGNOSIS

SEX

- Soft tissue swelling
- Mottled appearance of rostral mandibles

Neutered Male

INTERPRETATION OF THE FINDINGS & FURTHER RECOMMENDATIONS

AGE

12 Years

I can see no periapical lysis. The bony structure changes with increasing age but the bony mottling is associated with the soft tissue swelling; thus chronic inflammation and infection as well as tumour (though less likely) have to be considered. A CT examination is recommended to assess the bony changes and their extend better. The lymph nodes should be included in the examination to obtain a sample in case they are enlarged. A bone biopsy is necessary for a final diagnosis.

INTERPRETED BY

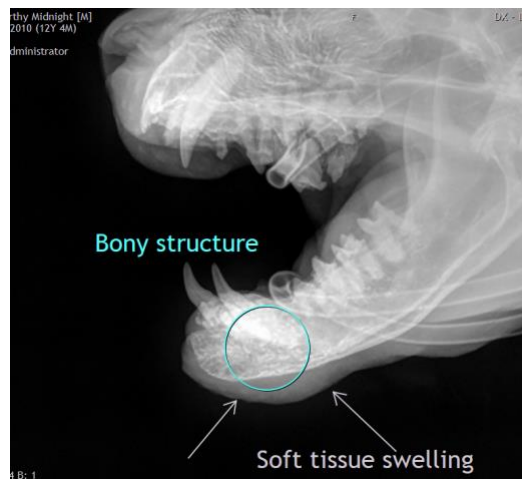
Heike Rudorf, DVM,
Dr. med. Vet.,
DipECVDDI DVR

HOSPITAL NAME

New Bridge VP

REFERRING VET

Dr. Abina Glennon



INVOICE

17876

The information and recommendations provided are based on the images presented by the referring veterinarian/sonographer. No evaluation can be communicated regarding pathology that was not visible in the image/video clips provided.

DATE

10/21/22

Thank you for this referral. If the clinical or image interpretation does not parallel your findings or if I can be of any further assistance please contact me.



PATIENT

Midnight McCarthy

Heike Rudolf, DVM, Dr. med. vet., DipECVDI, DVR
dr.h.rudorf@gmail.com

SPECIES

Feline

BREED

DSH

SEX

Neutered Male

AGE

12 Years

INTERPRETED BY

Heike Rudolf, DVM,
Dr. med. Vet.,
DipECVDI DVR

HOSPITAL NAME

New Bridge VP

REFERRING VET

Dr. Abina Glennon

INVOICE

17876

DATE

10/21/22