



PATIENT PRESENTING CLINICAL SIGNS

Louie Nagi History: Suspect IBD, intermittent inappetence, firm abdomen, on Pred 5mg (1/4 -1 T PO SID-EOD).

RADIOGRAPHIC STUDY OF THE ABDOMEN

SPECIES The body condition score is 9/9 with smooth alternating layers of fat and soft tissue opacity. The bony structures are within normal limits.

Feline

The abdominal detail is very good; diaphragm and abdominal wall are intact.

BREED The liver is located within the costal arch and the caudo-ventral lobe is pointed.

DMH The spleen appears slightly prominent with a small bulge on the medial aspect, level with L3.

SEX The stomach contains a moderate amount of food. Distribution and size of the small intestinal loops appear physiological; some loops contain gas, others fluid. Colon and rectum contain a moderate amount of formed feces.

Neutered Male

Both renal shadows have a physiological size, shape and opacity. The bladder is located in the abdominal cavity and contains a small amount of homogeneous fluid opacity.

AGE The sublumbar region appears physiological.

8 Years 5 Months

RADIOGRAPHIC DIAGNOSIS

- Small splenic prominence

INTERPRETED BY

INTERPRETATION OF THE FINDINGS & FURTHER RECOMMENDATIONS

Heike Rudolf, DVM,
Dr. med. Vet.,
DipECVDI DVR

The prominence at the spleen could be due to vessels at the hilus, a regenerative nodule or, less likely, hematoma or solitary growth. For the assessment of intestinal wall thickness and layering abdominal ultrasound is necessary. A full thickness sample may need to be obtained to confirm the diagnosis of IBD, which will alter the amount of corticosteroids used. Weight control is recommended.

HOSPITAL NAME

Reid VH

REFERRING VET

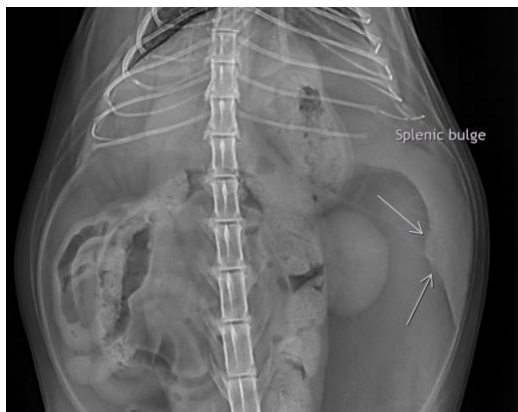
Dr. Diane Heider

INVOICE

17875

DATE

10/21/22





PATIENT The information and recommendations provided are based on the images presented by the referring veterinarian/sonographer. No evaluation can be communicated regarding pathology that was not visible in the image/video clips provided.

Louie Nagi

Thank you for this referral. If the clinical or image interpretation does not parallel your findings or if I can be of any further assistance please contact me.

SPECIES

Feline **Heike Rudolf**, DVM, Dr. med. vet., DipECVDI, DVR
dr.h.rudorf@gmail.com

BREED

DMH

SEX

Neutered Male

AGE

8 Years 5 Months

INTERPRETED BY

Heike Rudolf, DVM,
Dr. med. Vet.,
DipECVDI DVR

HOSPITAL NAME

Reid VH

REFERRING VET

Dr. Diane Heider

INVOICE

17875

DATE

10/21/22