



PATIENT PRESENTING CLINICAL SIGNS

Gizmo Cervero History: Hx of seizure like episodes, p very lethargic since monday, not eating or drinking
 Abnormal PE/Chem/CBC/UA Results: Respiratory distress, cyanotic, difficult to auscult due to breathing.

SPECIES RADIOGRAPHIC STUDY OF THE THORAX

Canine The body condition score is 8/9 with smooth alternating layers of fat and soft tissue opacity. The bony structures appear physiological.

BREED The degree of pulmonary expansion is fair at best. The lungs are in contact with the thoracic boundaries and the tips are pointed. The lobar vessels are poorly outlined and bronchial enhancement is present in both dorso-caudal lung lobes. The visible distal third of the vessels for the cranial lobes are small; the vascular outline for the caudal lobar vessels appears slightly undulating.

SEX The cranial mediastinum is of physiological size and opacity. The trachea runs parallel to the thoracic vertebrae and dips at the carina.

Neutered Male The cardiac silhouette occupies 75% of the chest height and 2.5 intercostal spaces (VHS11). A reversed D-shape is present on the DV with a mild prominence at 2 o'clock.

AGE RADIOGRAPHIC DIAGNOSIS

- 14 Years**
- Interstitial infiltrate caudal lobes
 - R sided cardiomegaly
 - Prominent pulmonary artery segment, mild
 - Small vessels

INTERPRETED BY

Heike Rudorf, DVM,
 Dr. med. Vet.,
 DipECVDI DVR

INTERPRETATION OF THE FINDINGS & FURTHER RECOMMENDATIONS

The changes are suggestive of pulmonary hypertension (possibly due to fibrosis) and secondary Cor pulmonale. Echocardiography is recommended to verify this. Ideally trachea-bronchoscopy and BAL should be performed to rule out inflammation and infection but this is contraindicated with severe respiratory sign due to potential problems during recovery. Liver diseases with secondary PSS should be ruled out with biochemistry and abdominal ultrasound. Cross sectional imaging of the brain is necessary to rule out a space occupying lesion as a cause for the seizures. Tracheal collapse can be present as well which will exacerbate the clinical signs.

HOSPITAL NAME

The pet Hospital of
 Stratford

Obesity is known to worsen clinical signs of cough and impair lung function; weight control is strongly recommended.

REFERRING VET

Dr. Claudia Giuliani,
 DVM

INVOICE

17874

DATE

10/21/22



PATIENT

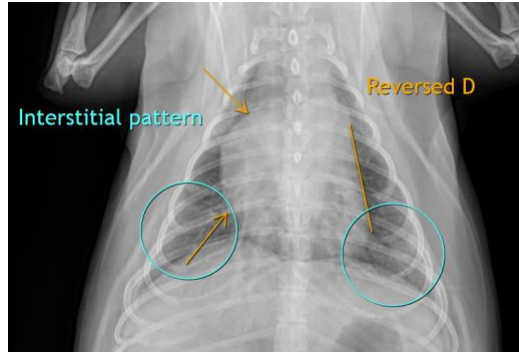
Gizmo Cervero

SPECIES

Canine

BREED

Pomeranian



The information and recommendations provided are based on the images presented by the referring veterinarian/sonographer. No evaluation can be communicated regarding pathology that was not visible in the image/video clips provided.

SEX

Neutered Male

Thank you for this referral. If the clinical or image interpretation does not parallel your findings or if I can be of any further assistance please contact me.

AGE

14 Years

Heike Rudolf, DVM, Dr. med. vet., DipECVDI, DVR
dr.h.rudorf@gmail.com

INTERPRETED BY

Heike Rudolf, DVM,
Dr. med. Vet.,
DipECVDI DVR

HOSPITAL NAME

The pet Hospital of
Strafford

REFERRING VET

Dr. Claudia Giuliani,
DVM

INVOICE

17874

DATE

10/21/22