

**PATIENT PRESENTING CLINICAL SIGNS**

**Cleo Nelson** History: Increased resp rate and effort. Grade 1 heart murmur. Hx of ulcers in her mouth suspect a herpes infection. Decreased appetite and weight loss. On mirtazapine which is helping with her appetite. Abdominal ultrasound last week suspicious for pancreatitis. On gabapentin for pain control. Abnormal PE/Chem/CBC/UA Results:

**SPECIES**

Feline

**RADIOGRAPHIC STUDY OF THE THORAX**

The body condition score is 7/9 with smooth alternating layers of fat and soft tissue opacity. L1 shows two differently developed ribs. Two intersternabral spaces are reduced.

**BREED**

DSH

The lungs are in contact with the thoracic boundaries and the tips are pointed. The clear vascular outline of the lobar vessels, especially the tertiary branches, is lost and the peripheral bronchi are highlighted.

**SEX**

Spayed Female

The visible part of the cranial mediastinum is superimposed by humeral muscles. The trachea diverges from the thoracic vertebrae and the carina is located at T5.

The cardiac silhouette occupies 75% of the chest height and 2 intercostal spaces. Both atria appear large which results in a Valentine shape of the cardiac silhouette on the VD view.

**AGE**

5 Years

**RADIOGRAPHIC DIAGNOSIS**

- Valentine shaped heart
- Interstitial pattern
- Congenital vertebral anomaly L1 (incidental finding)

**INTERPRETED BY**

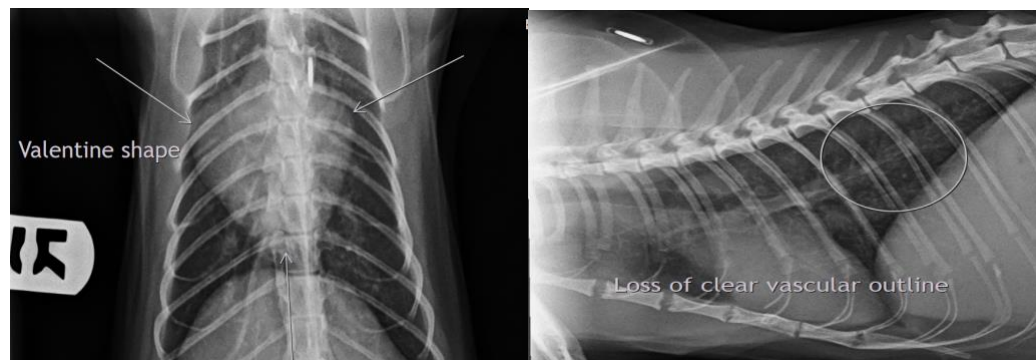
Heike Rudorf, DVM,  
Dr. med. Vet.,  
DipECVDDI DVR

**INTERPRETATION OF THE FINDINGS & FURTHER RECOMMENDATIONS**

The changes are highly suggestive of HCM with interstitial edema and echocardiography is recommended. Should this yield a normal result, trachea-bronchoscopy with BAL is recommended to differentiate between inflammation and infection.

**HOSPITAL NAME**

Windmere VH



**REFERRING VET**

Dr. Sherif Boctor

**INVOICE**

17872

**The information and recommendations provided are based on the images presented by the referring veterinarian/sonographer. No evaluation can be communicated regarding pathology that was not visible in the image/video clips provided.**

**DATE**

10/21/22



**PATIENT**

Thank you for this referral. If the clinical or image interpretation does not parallel your findings or if I can be of any further assistance please contact me.

Cleo Nelson

**Heike Rudolf**, DVM, Dr. med. vet., DipECVDI, DVR  
dr.h.rudorf@gmail.com

**SPECIES**

Feline

**BREED**

DSH

**SEX**

Spayed Female

**AGE**

5 Years

**INTERPRETED BY**

Heike Rudolf, DVM,  
Dr. med. Vet.,  
DipECVDI DVR

**HOSPITAL NAME**

Windmere VH

**REFERRING VET**

Dr. Sherif Boctor

**INVOICE**

17872

**DATE**

10/21/22