



PATIENT PRESENTING CLINICAL SIGNS

Jasper Tarrazas Patient is overweight. Very stiff on all joints. Excessive panting. HX of increased ALT. Abnormal PE/Chem/CBC/UA Results: ALT increase small amount (278 to 350)

SPECIES RADIOGRAPHIC STUDY OF THORAX, PELVIS AND STIFLES

Canine Thorax: 2x RLR, LLR, VD
Pelvis: 2 orthogonal views (VD includes stifles)
Stifles: R and L lateral

BREED RADIOGRAPHIC FINDINGS

Golden Retriever The body condition score is 8/9.

SEX The disc space between T5/6 and T9/10 is reduced and ventral spondylosis is present. A large amount of new bone is associated with both shoulder joints; it appears cauliflower like on one right lateral image. One glenoid appears shallow and a separate center of ossification is located on the caudal edge of the scapula.

Male Neutered

AGE Thorax

12 Years The lungs are in contact with the thoracic boundaries and the tips are pointed. The lobar vessels are visible. Calcification of the main stem bronchial walls is evident.

INTERPRETED BY

Heike Rudolf, DVM, Dr. med. Vet., DipECVDDI DVR The cranial mediastinum is of physiological size and opacity. The trachea runs parallel to the thoracic vertebrae and dips at the carina.

The cardiac silhouette occupies 75% of the chest height and 2.5 intercostal spaces (VHS 11). No chamber or outflow tract enlargement is evident.

HOSPITAL NAME

Baseline Animal Hospital **Pelvis**

Very little muscle mass surrounds both femora. Both femoral heads are severely subluxated with recontouring of the femoral heads and necks, shallow acetabula and calcified structures in the region of the joint capsule. Both femora appear slightly dorsally displaced on the lateral views.

REFERRING VET

Dr. Drachuk **Stifles**

The stifle joints have smooth, subchondral bone surfaces and the centre of the femoral condyles is in line with the intercondylar eminence. The cranial fat pad has a physiological size, and the caudal fascial plains are in a physiological position. New bone formation is not evident, and the patella is located in its groove.

INVOICE

47904

RADIOGRAPHIC DIAGNOSIS

DATE

10-21-21

- Shoulder arthrosis bilateral, severe
- HD and arthrosis, severe
- Incidental findings
- Bronchial wall mineralization



PATIENT

Jasper Tarrazas

- Spondylosis
- Discopathy

INTERPRETATION OF THE FINDINGS & FURTHER RECOMMENDATIONS

SPECIES

Canine

The severe shoulder and hip changes most likely cause pain, and this would account for the panting. Pain relieve should be re-assessed. Obesity is known to impair lung function; weight control is strongly recommended (especially considering the severe OA). The Retriever breed suffers from laryngeal paralysis which can cause panting and thus should be ruled out; this can be done with laryngoscopy and visual inspection or with the aid of ultrasound.

BREED

Golden Retriever

SEX

Male Neutered

AGE

12 Years

INTERPRETED BY

Heike Rudorf, DVM,
Dr. med. Vet.,
DipECVDI DVR

HOSPITAL NAME

Baseline Animal
Hospital

REFERRING VET

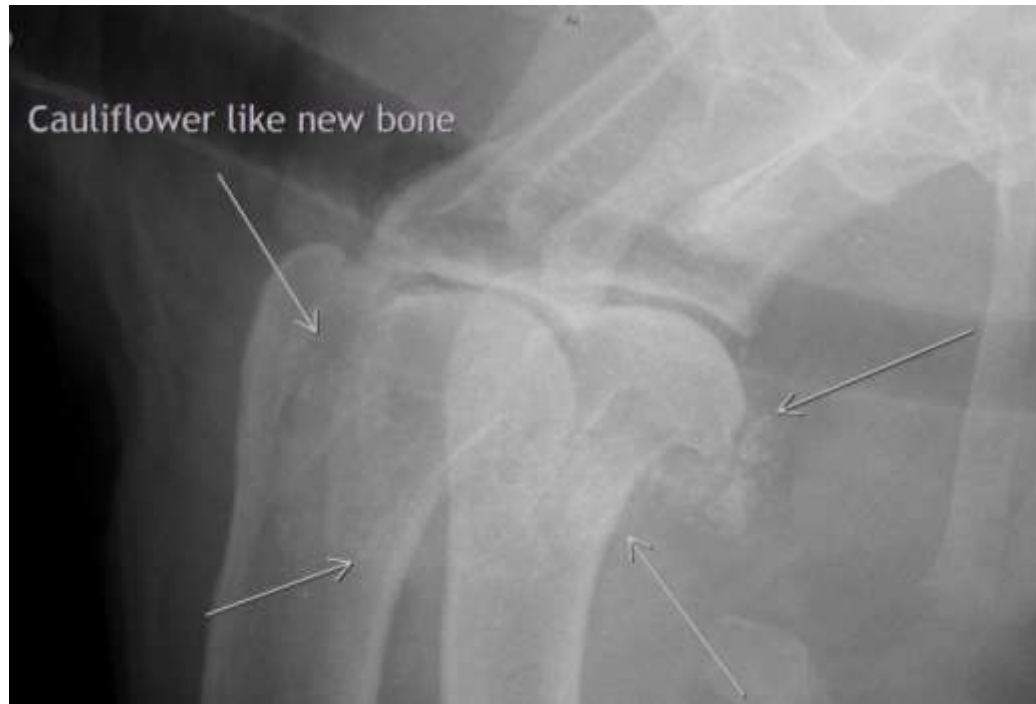Dr. Drachuk

INVOICE

47904

DATE

10-21-21





PATIENT

Jasper Tarrazas

SPECIES

Canine

BREED

Golden Retriever

SEX

Male Neutered

AGE

12 Years

INTERPRETED BY

Heike Rudolf, DVM,
Dr. med. Vet.,
DipECVDDI DVR

HOSPITAL NAME

Baseline Animal
Hospital

REFERRING VET

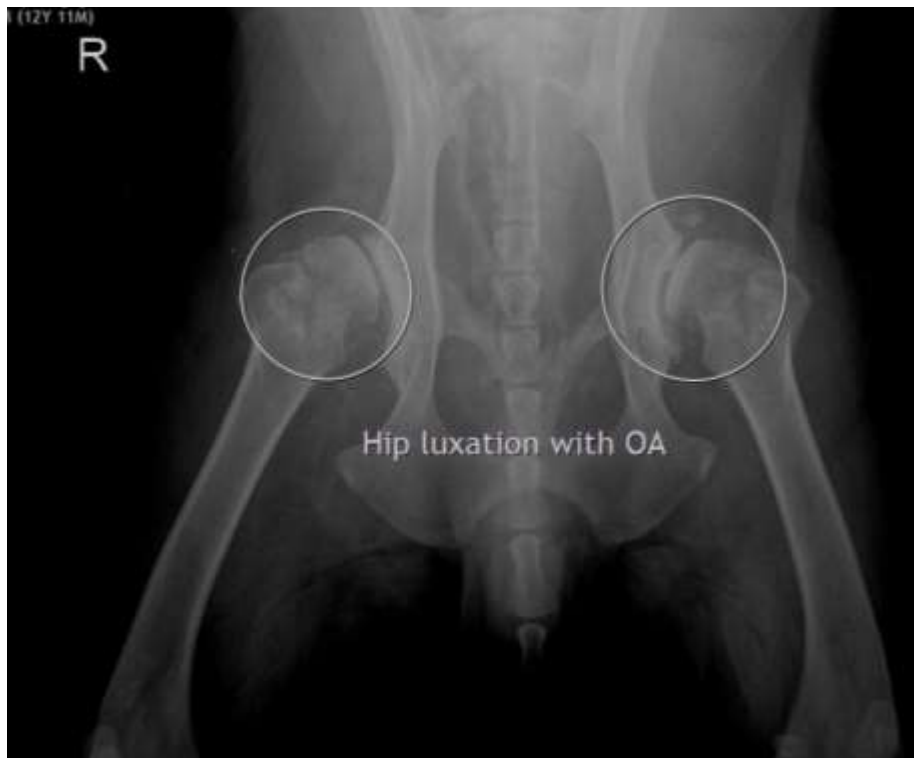
Dr. Drachuk

INVOICE

47904

DATE

10-21-21



The information and recommendations provided are based on the images presented by the referring veterinarian. No evaluation can be communicated regarding pathology that was not visible in the image/video clips provided.

Thank you for this referral. If the clinical or image interpretation does not parallel your findings or if I can be of any further assistance please contact me.

Heike Rudolf, DVM, Dr. med. vet., DipECVDDI, DVR
Dr.H.Rudorf@gmail.com