



**PATIENT**

Bayley Negrin

**PRESENTING CLINICAL SIGNS**

P presents for for blood in urine. P was placed on antibiotics and on the last day began with bloodyurine. O states that it has not improved. P will urinate in arge amounts in the am and the little puddles through out the day. P has been sleeping more but when active has accidents in the house, both urination and defecation. Urine varies from light pink to dark red and occurs at random. P is eating and drinking less. NO URINARY INCONTINENCE HAS HAD RECURRENT HEMATURIA THAT WILL IMPROVE WITH ANTIBIOTICS BUT WILL RECURR SHORTLY AFTER

**SPECIES**

Canine

**RADIOGRAPHIC STUDY OF THE ABDOMEN**

**BREED**

Pomeranian Mix

2 orthogonal views

**RADIOGRAPHIC FINDINGS**

**SEX**

Spayed Female

The body condition score is 8/9 with smooth alternating layers of fat and soft tissue opacity.

The L7/S1 disc space is reduced, mild endplate sclerosis and ventral spondylosis are present.

**AGE**

2 Years, 5 Months

Both renal shadows have a physiological size, shape and opacity; the surfaces are smooth. The bladder is located in the abdominal cavity and is filled with a large number of smooth, round to oval calculi.

The other abdominal structures are physiological.

**INTERPRETED BY**

Heike Rudorf, DVM,  
Dr. med. Vet.,  
DipECVDDI DVR

**RADIOGRAPHIC DIAGNOSIS**

- Bladder completely filled with cystic calculi
- Obesity
- Disc disease and spondylosis L7/S1 (incidental finding)

**HOSPITAL NAME**

DPC Veterinary  
Hospital

**INTERPRETATION OF THE FINDINGS & FURTHER RECOMMENDATIONS**

Surgery is necessary to remove all calculi. Prior to this, ultrasound of the kidneys should be performed to assess if the ureteral papillae are obstructed because this may have resulted in dilatation of the renal pelvises and/or ureters. Catheterization of the urethra will ensure than no calculus is located in its lumen.

**REFERRING VET**

Dr. Feldt

**TECHNICAL COMMENTS**

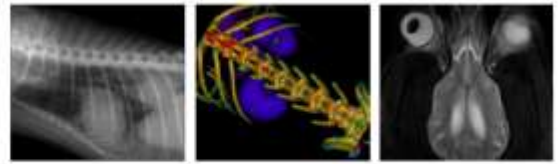
Human fingertips in primary beam on VD view.

**INVOICE**

47905

**DATE**

10-21-21



**PATIENT**

Bayley Negrin

The information and recommendations provided are based on the images presented by the referring veterinarian. No evaluation can be communicated regarding pathology that was not visible in the image/video clips provided.

**SPECIES**

Canine

Thank you for this referral. If the clinical or image interpretation does not parallel your findings or if I can be of any further assistance please contact me.

**BREED**

Pomeranian Mix

**Heike Rudolf**, DVM, Dr. med. vet., DipECVDI, DVR  
Dr.H.Rudorf@gmail.com

**SEX**

Spayed Female

**AGE**

2 Years, 5 Months

**INTERPRETED BY**

Heike Rudolf, DVM,  
Dr. med. Vet.,  
DipECVDI DVR

**HOSPITAL NAME**

DPC Veterinary  
Hospital

**REFERRING VET**

Dr. Feldt

**INVOICE**

47905

**DATE**

10-21-21