



## PRESENTING CLINICAL SIGNS

### PATIENT

Mya Charron  
History: sudden onset of limping from right hind  
Abnormal PE/Chem/CBC/UA Results:

### SPECIES

Canine

## RADIOGRAPHIC STUDY OF THE STIFLE

The skeletal structures are well mineralized, with physiological cortico-medullary development and differentiation.

### BREED

The stifle joint has smooth subchondral bone surfaces and the centre of the femoral condyles is in line with the intercondylar eminence. The cranial fat pad appears to have a physiological size and the caudal fascial plains appear to be in a physiological position. New bone formation is evident on the tip of the patella and on the tibial insertion of the cranial cruciate ligament.

### SEX

Spayed Female  
Soft tissue opacity at caudo-ventral body wall.

### AGE

## RADIOGRAPHIC DIAGNOSIS

11 Years  
• Mild arthrosis stifle

## INTERPRETATION OF THE FINDINGS & FURTHER RECOMMENDATIONS

The mild arthrosis is unlikely to represent the cause for the lameness. However, fiber disruption of the cruciate ligament is possible. Re-examination in 7 days is recommended. A foreign body or soft tissue injury may be easier to localize.

### INTERPRETED BY

Heike Rudorf, DVM,  
Dr. med. Vet.,  
DipECVDI DVR

A soft tissue mass in the inguinal region could represent a mammary tumor.

### HOSPITAL NAME

St. Catharine's AH

## TECHNICAL COMMENTS

Movement blur on lateral stifle view.

### REFERRING VET

Dr. Masoud

### INVOICE

13794

### DATE

10/15/21



**PATIENT**

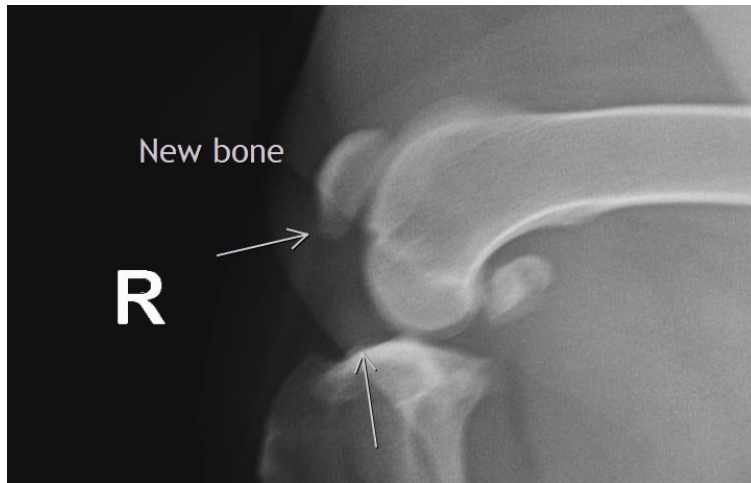
Mya Charron

**SPECIES**

Canine

**BREED**

Old English Shepherd



**SEX**

Spayed Female

**The information and recommendations provided are based on the images presented by the referring veterinarian. No evaluation can be communicated regarding pathology that was not visible in the image/video clips provided.**

**AGE**

11 Years

Thank you for this referral. If the clinical or image interpretation does not parallel your findings or if I can be of further assistance please contact me.

**Heike Rudorf**, DVM, Dr. med. vet., DipECVDI, DVR  
dr.h.rudorf@gmail.com

**INTERPRETED BY**

Heike Rudorf, DVM,  
Dr. med. Vet.,  
DipECVDI DVR

**HOSPITAL NAME**

St. Catharine's AH

**REFERRING VET**

Dr. Masoud

**INVOICE**

13794

**DATE**

10/15/21