



PATIENT **PRESENTING CLINICAL SIGNS**

Jax Legear
History: Chronic diarrhea
Abnormal PE/Chem/CBC/UA Results: Elevated Pancreatitis cPli

SPECIES **RADIOGRAPHIC STUDY OF THE ABDOMEN**

Canine
The body condition score is 7/9 with a large amount of subcutaneous fat dorsal to the sacrum.

BREED The bony structures are within normal limits.

German Shepherd
Mix
The abdominal detail is good; diaphragm and abdominal wall are intact.

The liver is located within the costal arch and the caudo-ventral lobe is pointed.

SEX The tail of the spleen is located level with L4/5 and extends cranially to the head of the spleen level with L1/2 resulting in an increased opacity caudal to the stomach where the body is located.

Neutered Male

The stomach contains a moderate amount of air; the small intestinal loops occupy the central abdomen and appear of homogeneous and physiological size. The terminal half of the descending colon and the rectum contain a moderate amount of gas. The thickness of the colonic wall in this region varies between 0.16 and 0.3 cm. The junction between colonic fluid and gas shows mild wall corrugation on the lateral view.

Both renal shadows have a physiological size, shape and opacity; the surfaces are smooth. The bladder is located in the abdominal cavity and contains a small amount of homogeneous fluid opacity.

INTERPRETED BY

Heike Rudolf, DVM,
Dr. med. Vet.,
DipECVDI DVR

The region of the sublumbar lymph nodes appears physiological.

RADIOGRAPHIC DIAGNOSIS

- Colonic wall size variation

HOSPITAL NAME

St. Catharine's AH

INTERPRETATION OF THE FINDINGS & FURTHER RECOMMENDATIONS

REFERRING VET

Dr. Boctor

The wall corrugation could be the result of superimposed small intestinal loops or could be caused by colitis. Variation in wall size on radiographs can be due to infiltrate or can be the result of a variation in luminal filling. The region caudal to the stomach could show an increased opacity due to the traversing body of the spleen or may be the result of pancreatic inflammation. Abdominal ultrasound is recommended to assess wall size and layering and to check the pancreas.

INVOICE

13795

DATE

10/15/21



PATIENT

Jax Legear

SPECIES

Canine

BREED

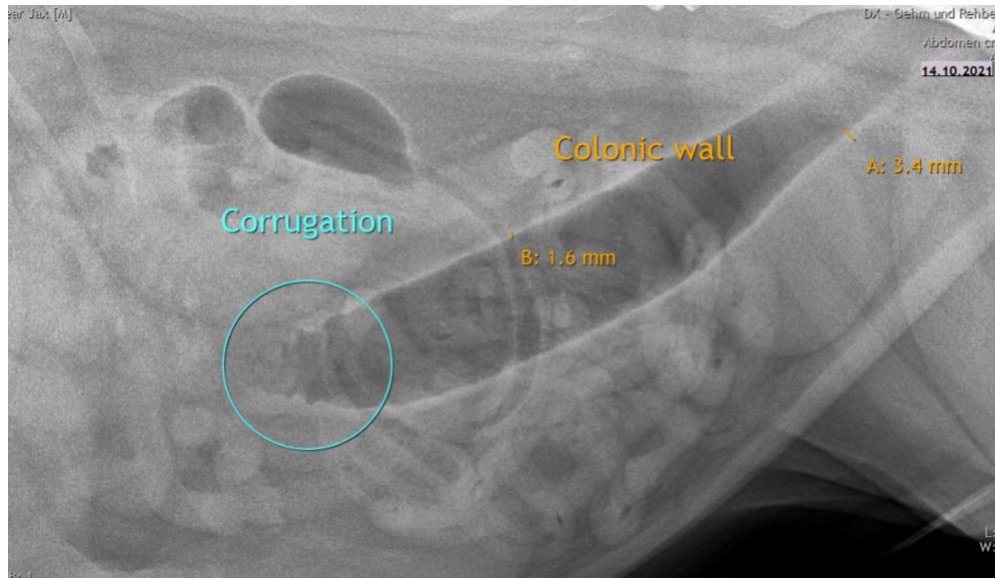
German Shepherd
Mix

SEX

Neutered Male

AGE

4 Years



The information and recommendations provided are based on the images presented by the referring veterinarian. No evaluation can be communicated regarding pathology that was not visible in the image/video clips provided.

Thank you for this referral. If the clinical or image interpretation does not parallel your findings or if I can be of any further assistance please contact me.

Heike Rudolf, DVM, Dr. med. vet., DipECVDI, DVR
dr.h.rudorf@gmail.com

INTERPRETED BY

Heike Rudolf, DVM,
Dr. med. Vet.,
DipECVDI DVR

HOSPITAL NAME

St. Catharine's AH

REFERRING VET

Dr. Boctor

INVOICE

13795

DATE

10/15/21