



PATIENT PRESENTING CLINICAL SIGNS

Bubbers Morrison History: History of chronic renal failure. Has been vomiting bile past couple days and started coughing. Appetite has decreased and did not eat anything today.

SPECIES Abnormal PE/Chem/CBC/UA Results: No crackles or wheezes. No heart murmur - coughing on and doff during the exam. Bloodwork showed stage 3 renal failure. Based on IRIS staging. Urinalysis: Canine specific gravity - 1.008

RADIOGRAPHIC STUDY OF THE THORAX

BREED

Shih Tzu The body condition score is 6/9 with smooth alternating layers of fat and soft tissue opacity. The bony structures appear physiological.

SEX

Spayed Female The degree of pulmonary expansion on the lateral views is fair at best. The lungs are in contact with the thoracic boundaries and the tips are pointed. On the VD view the lobar vessels are clearly visible to the tertiary branches. The bronchial tree is thin walled and tapers uniformly towards the periphery.

AGE

9 Years The cranial mediastinum is of physiological size and opacity. The tracheal path varies slightly depending on recumbency and position of the head. The lumen is homogeneously air filled.

The cardiac silhouette occupies 75% of the chest height and 2.25 intercostal spaces (VHS 8). No chamber or outflow tract enlargement is evident. The caudal heart border is straight. The cranial lobar vessel size is slightly reduced. The width of the caudal lobar vessels equals that of the 9th rib at their intersection with the rib.

INTERPRETED BY

Heike Rudolf, DVM, Dr. med. Vet., DipECVDI DVR

The pylorus is large on all views. All small intestinal loops are prominent and fluid filled.

RADIOGRAPHIC DIAGNOSIS

HOSPITAL NAME

- Truscott AH**
- Microcardia
 - Pyloric distension

INTERPRETATION OF THE FINDINGS & FURTHER RECOMMENDATIONS

REFERRING VET

Erini Abraham I can see no changes that would explain the cough. However, bronchitis can be present without radiographic evidence. Should the symptoms worsen or continue, tracheoscopy with BAL is recommended. The microcardia is most likely due to dehydration as a result of the vomiting. The cough could be due to inflammation of the upper respiratory tract mucosa due to the vomiting. Abdominal ultrasound is recommended to rule out pyloric obstruction.

INVOICE

13793

DATE

10/15/21



PATIENT

Bubbers Morrison

SPECIES

Canine

BREED

Shih Tzu

SEX

Spayed Female

AGE

9 Years

INTERPRETED BY

Heike Rudolf, DVM,
Dr. med. Vet.,
DipECVDI DVR

HOSPITAL NAME

Truscott AH

REFERRING VET

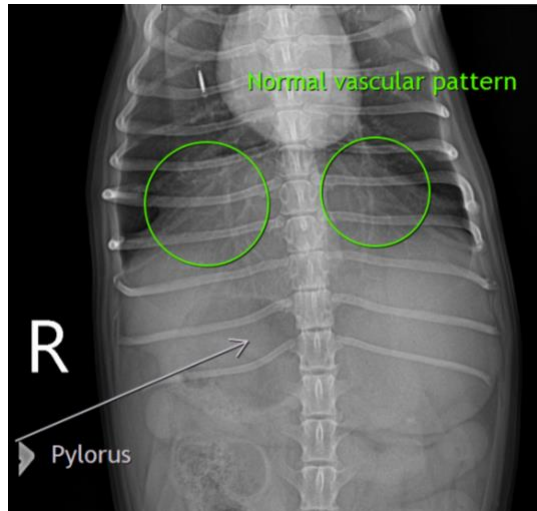
Erini Abraham

INVOICE

13793

DATE

10/15/21



The information and recommendations provided are based on the images presented by the referring veterinarian. No evaluation can be communicated regarding pathology that was not visible in the image/video clips provided.

Thank you for this referral. If the clinical or image interpretation does not parallel your findings or if I can be of any further assistance please contact me.

Heike Rudolf, DVM, Dr. med. vet., DipECVDI, DVR
dr.h.rudorf@gmail.com