



PATIENT PRESENTING CLINICAL SIGNS

Seattle Vannucci History: Hx of Hematuria and passing of marked blood clots in urine

SPECIES RADIOGRAPHIC STUDY OF THE ABDOMEN

Canine The body condition score is 5/9.

The xiphisternum is ventrally angled.

BREED The abdominal detail is reasonable; metal clips are present level with ovaries and uterus.

Coton de Tulear The liver is located within the costal arch and the caudo-ventral lobe is pointed.

SEX The spleen appears physiological.

Spayed Female The stomach contains a moderate amount of air; distribution and size of the small intestinal loops appear physiological. Colon and rectum contain a moderate amount of fecal matter.

AGE The left renal shadow has a physiological size, shape and opacity; the right is obscured by intestinal loops. An oval region of gas lucencies is located cranial to the pubic brim, in the region of the bladder shadow.

17 Years

The sublumbar region appears physiological.

INTERPRETED BY RADIOGRAPHIC DIAGNOSIS

Heike Rudolf, DVM, Dr. med. Vet., DipECVDI DVR

- Gas pockets in the region of the urinary bladder

INTERPRETATION OF THE FINDINGS & FURTHER RECOMMENDATIONS

HOSPITAL NAME The small gas stipples appear to be located in the region of the urinary bladder and would then likely represent gas forming organisms; this is usually associated with Diabetes mellitus. Further examinations are necessary to rule out gas filled small intestinal loops in this region. Abdominal ultrasound, retrograde urethrocytography and urinary samples are recommended. Examination of the kidneys will rule out hydronephrosis and blood clots in the renal pelvices.

Summit Dog & Cat

REFERRING VET TECHNICAL COMMENTS

Dr. Vogler Human fingers are present in the primary beam.

INVOICE

17699

DATE

10/13/22



PATIENT

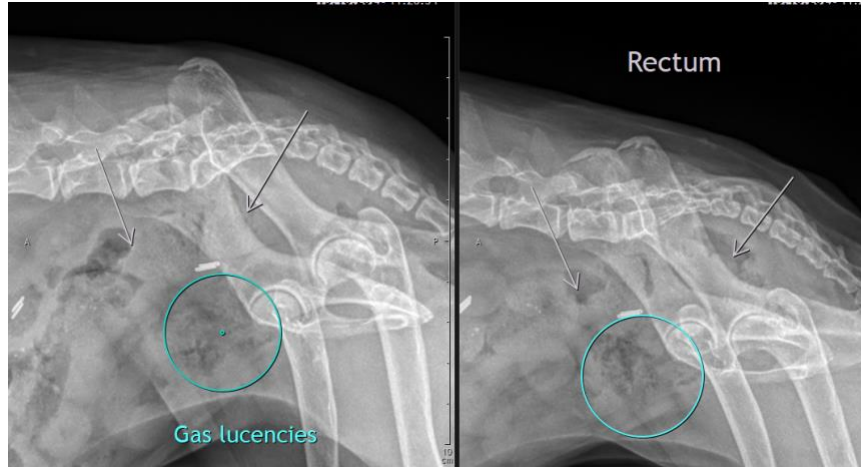
Seattle Vannucci

SPECIES

Canine

BREED

Coton de Tulear



SEX

Spayed Female

The information and recommendations provided are based on the images presented by the referring veterinarian/sonographer. No evaluation can be communicated regarding pathology that was not visible in the image/video clips provided.

AGE

17 Years

Thank you for this referral. If the clinical or image interpretation does not parallel your findings or if I can be of any further assistance please contact me.

Heike Rudorf, DVM, Dr. med. vet., DipECVDI, DVR
dr.h.rudorf@gmail.com

INTERPRETED BY

Heike Rudorf, DVM,
Dr. med. Vet.,
DipECVDI DVR

HOSPITAL NAME

Summit Dog & Cat

REFERRING VET

Dr. Vogler

INVOICE

17699

DATE

10/13/22