



PATIENT PRESENTING CLINICAL SIGNS

Hazel Racine History: history of right lateral suture surgery four months ago owner mentioned that patient still limping on the right hind leg, patient finished the course of PT and laser therapy

SPECIES RADIOGRAPHIC STUDY OF THE PELVIS AND STIFLES

Canine The medial cortex of the proximal right tibia is thin and appears interrupted and circularly twisted.

Pelvis

BREED The bones have a physiological trabecular structure and smooth surfaces. Both joints appear symmetrical on the lateral view.

Mini Poodle

R Stifle

SEX A soft tissue swelling surrounds the joint. The cranial fat pad is markedly reduced and the caudal fascial plains are obliterated by a soft tissue opacity which extends in a semi-circular fashion caudally for approx. 1cm. A small amount of new bone (NB) formation is present on the dorsal patella and tibial plateau. The caudal cortex of the distal femur and one femoral ridge have an irregular outline. The patella is superimposed onto the lateral condyle and the medial joint space is wider than the lateral one.

Neutered Male

AGE

7 Years

RADIOGRAPHIC DIAGNOSIS

- Joint swelling and effusion
- Patella luxation
- Variation in joint space size
- Mild arthrosis

INTERPRETED BY

Heike Rudorf, DVM, Dr. med. Vet., DipECVDI DVR

INTERPRETATION OF THE FINDINGS & FURTHER RECOMMENDATIONS

The joint swelling is most likely due to infection, differential diagnoses are inflammation and fibrosis. A synovial tap should be obtained. The location of the patella suggests a luxation. The appearance of the tibia could be due to an excessive rotation rather than a healed fracture. Damage to the origin of the gastrocnemius tendon or infection may have caused the irregular outline of the caudal femoral cortex.

HOSPITAL NAME

Animal Surgical Center

TECHNICAL COMMENTS

REFERRING VET

VD pelvis tilted to right side.

Garden City Park AH

INVOICE

17697

DATE

10/13/22



PATIENT

Hazel Racine

SPECIES

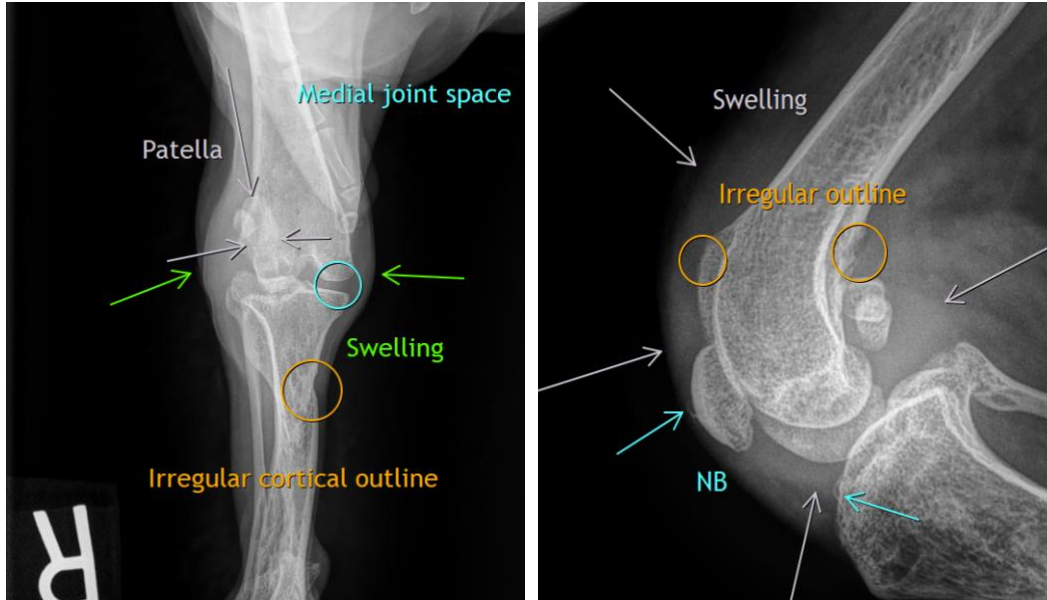
Canine

BREED

Mini Poodle

SEX

Neutered Male



AGE

7 Years

The information and recommendations provided are based on the images presented by the referring veterinarian/sonographer. No evaluation can be communicated regarding pathology that was not visible in the image/video clips provided.

Thank you for this referral. If the clinical or image interpretation does not parallel your findings or if I can be of any further assistance please contact me.

INTERPRETED BY

Heike Rudorf, DVM,
Dr. med. Vet.,
DipECVDI DVR

Heike Rudorf, DVM, Dr. med. vet., DipECVDI, DVR
dr.h.rudorf@gmail.com

HOSPITAL NAME

Animal Surgical
Center

REFERRING VET

Garden City Park AH

INVOICE

17697

DATE

10/13/22