



**PATIENT PRESENTING CLINICAL SIGNS**

**Dutch Denson** History: History: 5 y 4 m Yorkshire Terrier presented for possibly injuring front left leg. o noticed yesterday that when she felt the paw pad it appeared to be sharp.

**SPECIES** Abnormal PE/Chem/CBC/UA Results: Physical Examination Key -- (N= Normal, A= Abnormal) Oral cavity: Mild dental tartar Musculoskeletal: BCS = 6/9. Ambulatory x 4. LF= grade 3/5 lameness, painful on carpus manipulation/palpation, unable to flex this joint, no obvious external wounds. Radiographs: consult pending

**Canine**

**BREED RADIOGRAPHIC STUDY OF THE CARPI**

**Yorkshire Terrier** A small soft tissue swelling is located dorsal to the radio-carpal joint.

**SEX** A seemingly separate and distally displaced 0.2cm x 0.1cm bone opacity is evident distal to the cranial radius. The bones have a normal trabecular structure. Cortical-medullary development and differentiation of the long bones are physiological.

**Neutered Male RADIOGRAPHIC DIAGNOSIS**

- Mild swelling dorsal to radio-carpal joint
- Possible fragment off distal radius

**AGE INTERPRETATION OF THE FINDINGS & FURTHER RECOMMENDATIONS**

5 Years 4 Months

It is possible that the apparent fragment is due to highlighting the medial aspect of the radius. More views are required for appropriate assessment: a lateral view with carpal bone IV and accessory carpal bone superimposed onto each other as well as DLPMO and PLDMO view. Alternatively, a CT examination can be performed.

**INTERPRETED BY**

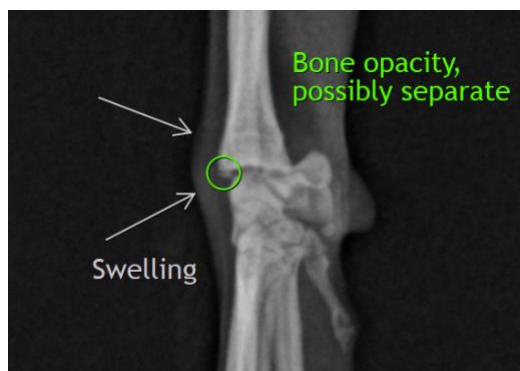
Heike Rudorf, DVM,  
Dr. med. Vet.,  
DipECVDI DVR

**HOSPITAL NAME**

DPC Veterinary  
Hospital

**REFERRING VET**

Dr. Rivera



**The information and recommendations provided are based on the images presented by the referring veterinarian/sonographer. No evaluation can be communicated regarding pathology that was not visible in the image/video clips provided.**

**INVOICE**

17694

Thank you for this referral. If the clinical or image interpretation does not parallel your findings or if I can be of any further assistance please contact me.

**DATE**

10/13/22



**PATIENT**

Dutch Denson **Heike Rudolf**, DVM, Dr. med. vet., DipECVDI, DVR  
dr.h.rudorf@gmail.com

**SPECIES**

Canine

**BREED**

Yorkshire Terrier

**SEX**

Neutered Male

**AGE**

5 Years 4 Months

**INTERPRETED BY**

Heike Rudolf, DVM,  
Dr. med. Vet.,  
DipECVDI DVR

**HOSPITAL NAME**

DPC Veterinary  
Hospital

**REFERRING VET**

Dr. Rivera

**INVOICE**

17694

**DATE**

10/13/22