



PRESENTING CLINICAL SIGNS

PATIENT

Lily Altobelli

History: history of PU/PD and slight azotemia, recently o noted bloody discharge from vulva; no blood noted in urine; UA and Uculture last month NSF (low USG), pt also had a seizure like episode this am after coughing (cannot r/o syncope vs vagal episode vs seizure vs open)

SPECIES

Canine

Abnormal PE/Chem/CBC/UA Results: small amount blood noted in vestibule on otoscopic vulvar exam; rest PE NSF; AG mildly full

RADIOGRAPHIC STUDY OF THE ABDOMEN

BREED

Beagle

The body condition score is 7/9 with smooth alternating layers of fat and soft tissue opacity.

The disc spaces between T13/L1, L2/3 and L4/5 are reduced or collapsed with sclerotic endplates and ventral spondylosis.

SEX

Spayed Female

The liver is located within the costal arch and the caudo-ventral lobe is pointed.

Spleen and kidneys are obscured by intestinal loops.

AGE

15 Years

The stomach appears to be empty. Small intestinal loops occupy the entire abdomen. Colon and rectum contain a small amount of formed fecal matter and gas.

The bladder is located in the abdominal cavity and contains a small amount of homogeneous fluid opacity. A semicircular, soft tissue opacity appears to be located just cranial to the pubic brim in left lateral recumbency.

INTERPRETED BY

Heike Rudolf, DVM,
Dr. med. Vet.,
DipECVDI DVR

The region of the sublumbar lymph nodes appears physiological.

RADIOGRAPHIC DIAGNOSIS

- Soft tissue opacity between bladder and pubic brim

HOSPITAL NAME

Boca Park AH

Incidental findings

- Chronic disc disease
- Spondylosis

REFERRING VET

Morgan Spaulding

INTERPRETATION OF THE FINDINGS & FURTHER RECOMMENDATIONS

The soft tissue opacity cranial to the pubic brim could represent an artefact due to superimposed muscle tissue of the hind limb; however, uterine stump and urethral tumor should be ruled out ultrasonographically. This will allow assessment of the other organs for signs of chronic renal failure, Diabetes mellitus and Cushing's disease. Small vaginal tumors can be easily missed on visual inspection; a retrograde vagino-urethrogram with full distension of the vagina can help identify mucosal irregularities.

INVOICE

13409

DATE

10/1/21



PATIENT

Lily Altobelli

SPECIES

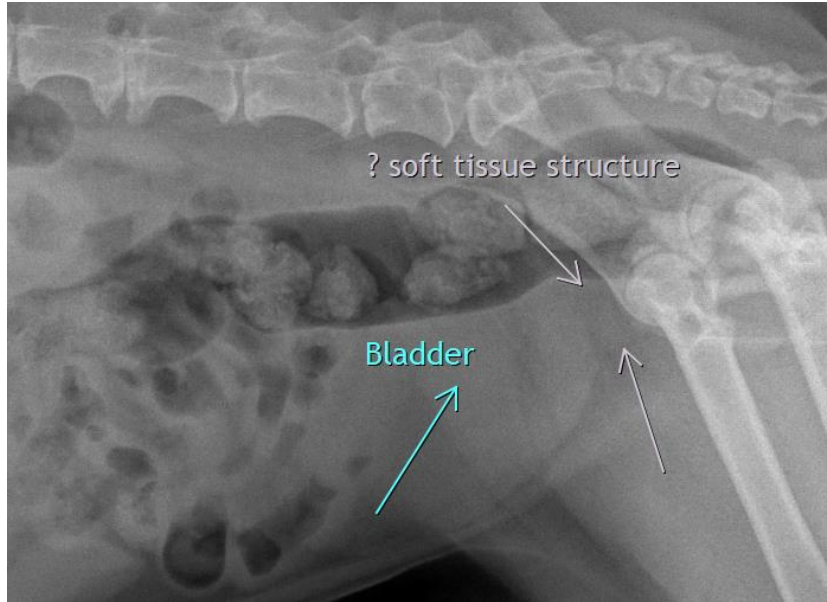
Canine

BREED

Beagle

SEX

Spayed Female



AGE

15 Years

The information and recommendations provided are based on the images presented by the referring veterinarian. No evaluation can be communicated regarding pathology that was not visible in the image/video clips provided.

Thank you for this referral. If the clinical or image interpretation does not parallel your findings or if I can be of any further assistance please contact me.

INTERPRETED BY

Heike Rudolf, DVM, Dr. med. vet., DipECVDI, DVR
dr.h.rudorf@gmail.com

Heike Rudolf, DVM,
Dr. med. Vet.,
DipECVDI DVR

HOSPITAL NAME

Boca Park AH

REFERRING VET

Morgan Spaulding

INVOICE

13409

DATE

10/1/21