



**PRESENTING CLINICAL SIGNS**

**PATIENT**

Geno Mendez

History: Lame on right front leg since the end of August. Painful when right shoulder touched awake and under sedation.

Abnormal PE/Chem/CBC/UA Results:

**SPECIES**

Canine

**RADIOGRAPHIC STUDY OF THE SHOULDERS**

**Right Humerus**

**BREED**

Irish Wolfhound

The cranio-proximal soft tissue is slightly cranially displaced from the proximal cortical surface.

The periosteal surface of the cranial cortex shows spikey new bone. The caudal cortex shows a large amount of layered new bone; in its central portion, a moth-eaten appearance is evident due to endosteal lysis. The medulla just distal to the bicipital groove shows a mushroom shaped lysis which extends distally into the diaphysis, resulting in a mottled, granular appearance.

**SEX**

Neutered Male

**RADIOGRAPHIC DIAGNOSIS**

- Tumor proximal right humerus

**AGE**

7 Years

**INTERPRETATION OF THE FINDINGS & FURTHER RECOMMENDATIONS**

The tumor is most likely an osteosarcoma. Examination of the thorax is necessary to look for metastases which is best done with CT but radiographs will suffice to identify large nodules. I can see no obvious metastases in the included part of the lungs.

**INTERPRETED BY**

Heike Rudorf, DVM,  
Dr. med. Vet.,  
DipECVDI DVR

**HOSPITAL NAME**

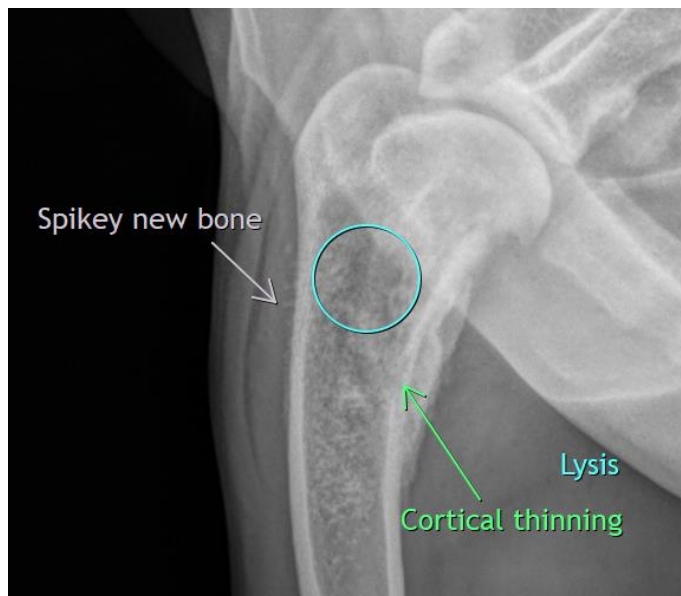
Harmony AH

**REFERRING VET**

Dr. Keefe

**INVOICE**

13411



The information and recommendations provided are based on the images presented by the

**DATE**

10/1/21



**PATIENT**

**referring veterinarian. No evaluation can be communicated regarding pathology that was not visible in the image/video clips provided.**

Geno Mendez Thank you for this referral. If the clinical or image interpretation does not parallel your findings or if I can be of any further assistance please contact me.

**SPECIES**

**Heike Rudolf**, DVM, Dr. med. vet., DipECVDI, DVR  
dr.h.rudorf@gmail.com

Canine

**BREED**

Irish Wolfhound

**SEX**

Neutered Male

**AGE**

7 Years

**INTERPRETED BY**

Heike Rudolf, DVM,  
Dr. med. Vet.,  
DipECVDI DVR

**HOSPITAL NAME**

Harmony AH

**REFERRING VET**

Dr. Keefe

**INVOICE**

13411

**DATE**

10/1/21