



PATIENT

Patch Bernard

SPECIES

Canine

BREED

Red Heeler Mix

SEX

Spayed Female

AGE

13 Years

WEIGHT

52.6 Pounds

INTERPRETED BY

Heike Rudolf, DVM, Dr.
med. Vet., DipECVDI
DVR

IMAGING PERFORMED BY

Katy

HOSPITAL NAME

Elizabeth AH

REFERRING VET

Leon Anderson, DVM

INVOICE

35352

DATE

1/9/26

PRESENTING CLINICAL SIGNS

History: Has a mass around the anus for a few months that is getting removed next week -Chest x-ray to check for mets

Abnormal PE/Chem/CBC/UA Results: PE: Anal Glands: External palpation is normal. Mild anal gland fill only. Rectal examination WNL, no subiliac pain or swelling. Coat/Skin: Mass around anus, 1.5 cm with a bleeding point on the most outward extremity; nails due for a trim

RADIOGRAPHIC STUDY OF THE THORAX

The body condition score is 6-7/9 with smooth, alternating layers of fat and soft tissue opacity.

The bony structures appear physiological.

The cranial mediastinum is of physiologic size and opacity. The trachea diverges from the thoracic vertebrae, and the carina is located level with T5.

The lung lobes are well aerated and extend to the thoracic boundaries. Pulmonary vessels are well outlined to the tertiary branches. The central bronchial tree is calcified and the bronchi taper towards the periphery. In right lateral recumbency a nodular opacity of 0.3cm diameter is located ventral to the caudal vena cava and superimposed by a longitudinal vessel.

The cardiac silhouette occupies 75% of the chest height and 2.5 intercostal spaces. Chamber or outflow tract enlargement is not obvious.

RADIOGRAPHIC DIAGNOSIS

- Possible lung nodule
- Bronchial wall calcification

INTERPRETATION OF THE FINDINGS & FURTHER RECOMMENDATIONS

The apparent nodule may represent a composite shadow of end- on and longitudinal vessels but metastasis cannot be ruled out. Follow up inspiratory radiographs can be obtained. I suggest to go ahead with the surgery and wait for the pathological results. In case it is a malignancy, CT of thorax and abdomen is recommended.



PATIENT

Patch Bernard

SPECIES

Canine

BREED

Red Heeler Mix

SEX

Spayed Female

AGE

13 Years

WEIGHT

52.6 Pounds

INTERPRETED BY

Heike Rudorf, DVM, Dr.
med. Vet., DipECVDI
DVR

IMAGING PERFORMED BY

Katy

HOSPITAL NAME

Elizabeth AH

REFERRING VET

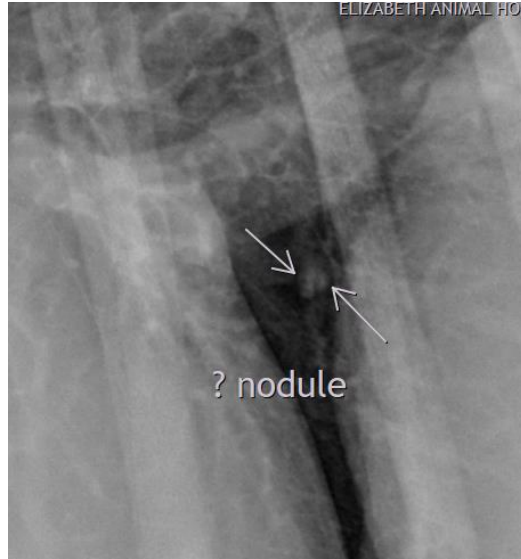
Leon Anderson, DVM

INVOICE

35352

DATE

1/9/26



The information and recommendations provided are based on the images presented by the referring veterinarian/sonographer. No evaluation can be communicated regarding pathology that was not visible in the image/video clips provided.

Thank you for this referral. If the clinical or image interpretation does not parallel your findings or if I can be of any further assistance, please contact me.

Heike Rudorf, DVM, Dr. med. vet., DipECVDI, DVR
info@sonopath.com