

**PATIENT**

Tashi Stringer

**PRESENTING CLINICAL SIGNS**

Cloth ingestion a few days ago and also had simple bloat by eating many pounds of dog food. These are follow up radiographs.  
Abnormal PE/Chem/CBC/UA Results: Normal PE

**SPECIES**

Canine

**RADIOGRAPH OF THE ABDOMEN**

RLR, VD

**BREED**

Golden Retriever

**RADIOGRAPHIC FINDINGS**

The body condition score is 6/9 with smooth alternating layers of fat and soft tissue opacity.

The bony structures are within normal limits.

**SEX**

Nonneutered Male

The abdominal detail is good; diaphragm and abdominal wall are intact.

**AGE**

11 Years

The stomach contains a mixture of air and fluid. Small intestinal loops in the right and cranial abdomen are slightly distended and have a streaky appearance due to linear, soft tissue opacities alternating with gas. Descending colon and rectum contain a moderate amount of formed fecal matter.

The other abdominal organs appear physiological.

**INTERPRETED BY**

Heike Rudorf, DVM,  
Dr. med. Vet.,  
DipECVDI DVR

**RADIOGRAPHIC DIAGNOSIS**

Cloth foreign body with localized ileus

**HOSPITAL NAME**

Pinebrook Animal  
Hospital

**INTERPRETATION OF THE FINDINGS & FURTHER RECOMMENDATIONS**

The changes are compatible with a cloth foreign body in the small intestine. Considering the length of time between ingestion of the foreign body and these radiographs, surgery is recommended.

**REFERRING VET**

Dr. Britt Dubil

**INVOICE**

49392

**DATE**

1-7-22



**PATIENT**

Tashi Stringer

**SPECIES**

Canine

**BREED**

Golden Retriever

**SEX**

Nonneutered Male

**AGE**

11 Years

**INTERPRETED BY**

Heike Rudorf, DVM,  
Dr. med. Vet.,  
DipECVDI DVR

**HOSPITAL NAME**

Pinebrook Animal  
Hospital

**REFERRING VET**

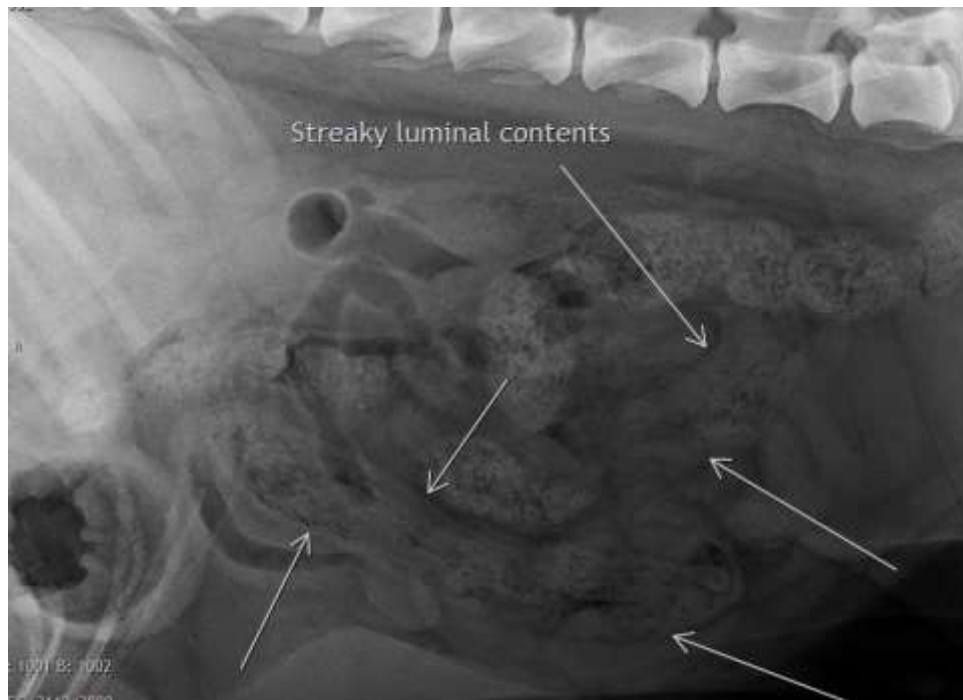
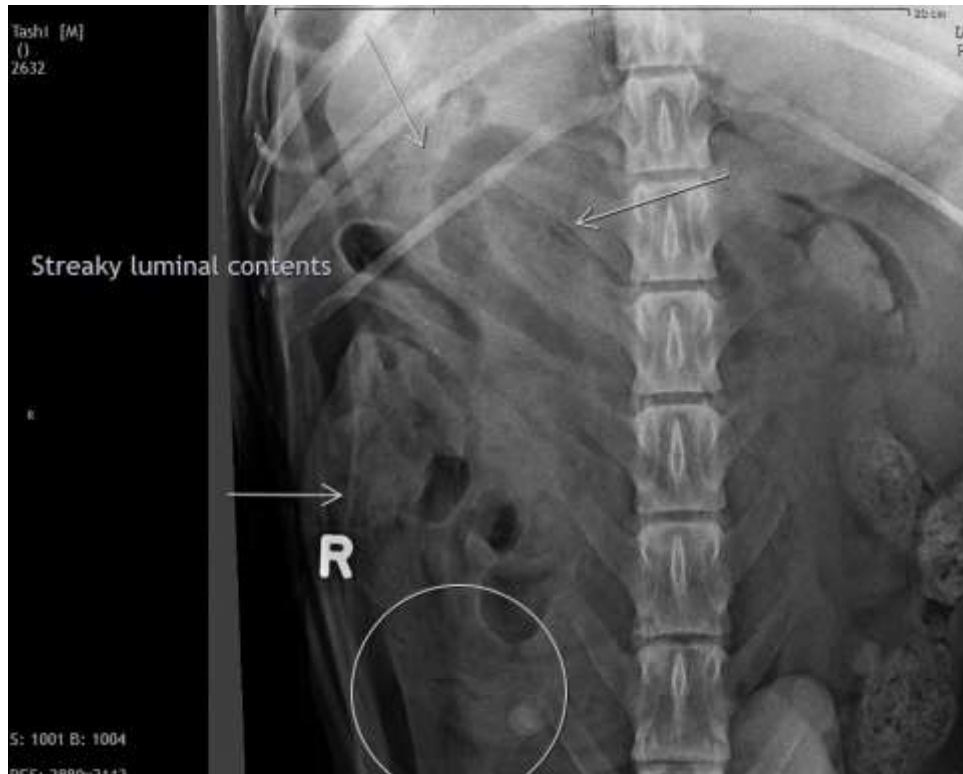Dr. Britt Dubil

**INVOICE**

49392

**DATE**

1-7-22





**PATIENT**

Tashi Stringer

The information and recommendations provided are based on the images presented by the referring veterinarian. No evaluation can be communicated regarding pathology that was not visible in the image/video clips provided.

**SPECIES**

Canine

Thank you for this referral. If the clinical or image interpretation does not parallel your findings or if I can be of any further assistance please contact me.

**BREED**

Golden Retriever

**Heike Rudorf, DVM, Dr. med. vet., DipECVDI, DVR**  
Dr.H.Rudorf@gmail.com

**SEX**

Nonneutered Male

**AGE**

11 Years

**INTERPRETED BY**

Heike Rudorf, DVM,  
Dr. med. Vet.,  
DipECVDI DVR

**HOSPITAL NAME**

Pinebrook Animal  
Hospital

**REFERRING VET**

Dr. Britt Dubil

**INVOICE**

49392

**DATE**

1-7-22