



PATIENT PRESENTING CLINICAL SIGNS

Nigel Everett Pt has had dry non-productive cough that has not resolved over the past week. Doctor is suspicious of- collapsing trachea, heart disease, and/or neoplasia.

SPECIES RADIOGRAPH OF THE THORAX

Canine 1x lateral neck; RLR, LLR, DV thorax

BREED RADIOGRAPHIC FINDINGS

Chihuahua Mix The body condition score is 7/9 with smooth alternating layers of fat and soft tissue opacity.

The bony structures appear physiological.

SEX The lungs are in contact with the thoracic boundaries and the tips are pointed. The lobar vessels are clearly visible to the tertiary branches on the DV view. The bronchial tree is thin walled, and the walls of the main bronchi are calcified.

Neutered Male

AGE The cranial mediastinum is of physiological size and opacity. The tracheal air space is between C4 and T1 reduced by a crescent shaped, dorsal soft tissue opacity.

9 Years

The cardiac silhouette occupies 75% of the chest height and 3 intercostal spaces. No obvious chamber or outflow tract enlargement is evident.

INTERPRETED BY

Heike Rudolf, DVM,
Dr. med. Vet.,
DipECVDI DVR

RADIOGRAPHIC DIAGNOSIS

- Tracheal collapse

HOSPITAL NAME

Ahwatukee Commons
Veterinary Hospital

INTERPRETATION OF THE FINDINGS & FURTHER RECOMMENDATIONS

Tracheal collapse alone can be due to a weakened dorsal tracheal ligament. Tracheal in combination with bronchial collapse is usually caused by chondromalacia and is thus due to an altered cartilage development which may go unnoticed until physical circumstances (such as stress, running, excitement) or disease (e.g. pneumonia, bronchitis, L cardiac enlargement) reduces the ease of airflow. Echocardiography to assess mitral valve and L atrial size. Bronchoscopy to check for bronchial collapse and to obtain a BAL is recommended because peribronchial infiltrate can be present without radiographic evidence. Should an underlying disease be present treatment may improve the clinical signs.

REFERRING VET

Dr. Rebecca R.
Housley

Obesity is known to worsen clinical signs of cough and impair lung function; weight control is recommended.

INVOICE

49391

DATE

1-7-22



PATIENT

Nigel Everett

SPECIES

Canine

BREED

Chihuahua Mix

SEX

Neutered Male

AGE

9 Years

INTERPRETED BY

Heike Rudolf, DVM,
Dr. med. Vet.,
DipECVDI DVR

HOSPITAL NAME

Ahwatukee Commons
Veterinary Hospital

REFERRING VET

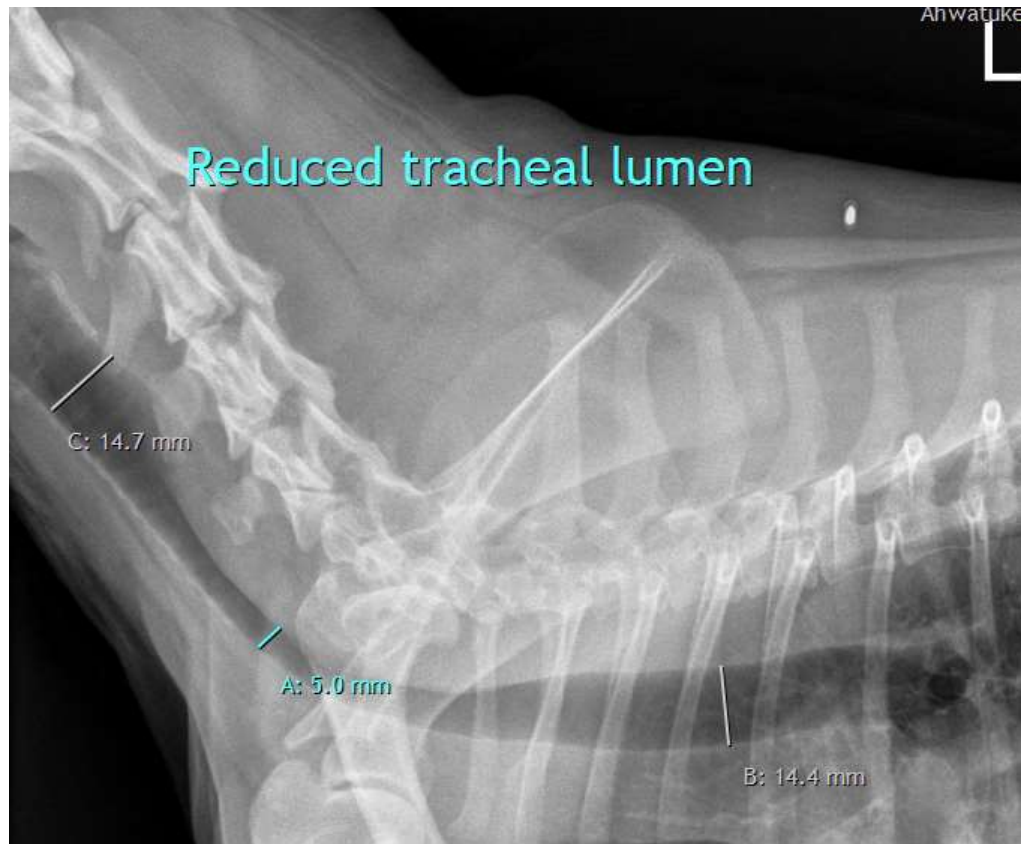
Dr. Rebecca R.
Housley

INVOICE

49391

DATE

1-7-22



The information and recommendations provided are based on the images presented by the referring veterinarian. No evaluation can be communicated regarding pathology that was not visible in the image/video clips provided.

Thank you for this referral. If the clinical or image interpretation does not parallel your findings or if I can be of any further assistance please contact me.

Heike Rudolf, DVM, Dr. med. vet., DipECVDI, DVR
Dr.H.Rudorf@gmail.com