

**PATIENT**

King Irwin

PRESENTING CLINICAL SIGNS

Long bone cancer, checking for Pulmonary metastasis

SPECIES

Canine

RADIOGRAPH OF THE THORAX

RLR, LLR

BREED

Great Dane

Mild ventral spondylosis is present in the caudal thoracic spine.

SEX

Male

The lungs are in contact with the thoracic boundaries and the tips are pointed. The lobar vessels are clearly visible to the tertiary branches. The bronchial tree is thin walled and tapers uniformly towards the periphery. In left lateral recumbency a roundish increased soft tissue opacity is superimposed over the ventral aspect of the caudal vena cava (CVC), dorsal to an end-on bronchus.

The cranial mediastinum is of physiological size and opacity. In the right lateral recumbent view a crescent shaped soft tissue opacity is located dorsal to the first two fully visible sternbrae.

AGE

8 Years, 4 Months

The cardiac silhouette occupies 70% of the chest height and 2.5 intercostal spaces. No chamber or outflow tract enlargement is evident.

INTERPRETED BY

Heike Rudolf, DVM,
Dr. med. Vet.,
DipECVDDI DVR

RADIOGRAPHIC DIAGNOSIS

- Localized increased opacity overlying CVC
- Possible sternal lymphadenomegaly, mild

HOSPITAL NAME

All Creatures Animal
Hospital of South Hill,
Inc.

INTERPRETATION OF THE FINDINGS & FURTHER RECOMMENDATIONS

The opacity overlying the CVC most likely represents an end-on blood vessel, but a metastasis cannot be ruled out. The opacity in the region of the sternal lymph node is most likely the result of artefacts but could be an early sign of lymph node enlargement. I suggest to either repeat the two lateral recumbent views with the fore legs extremely pulled cranially and inflated lungs (e.g. prior to surgery), especially if the tumor is located in the fore limb. CT, however, would be the imaging modality of choice for small changes.

REFERRING VET

Dr. Coe Lindner

INVOICE

49386

DATE

1-7-22



PATIENT

King Irwin

SPECIES

Canine

BREED

Great Dane

SEX

Male

AGE

8 Years, 4 Months

INTERPRETED BY

Heike Rudorf, DVM,
Dr. med. Vet.,
DipECVDDI DVR

HOSPITAL NAME

All Creatures Animal
Hospital of South Hill,
Inc.

REFERRING VET

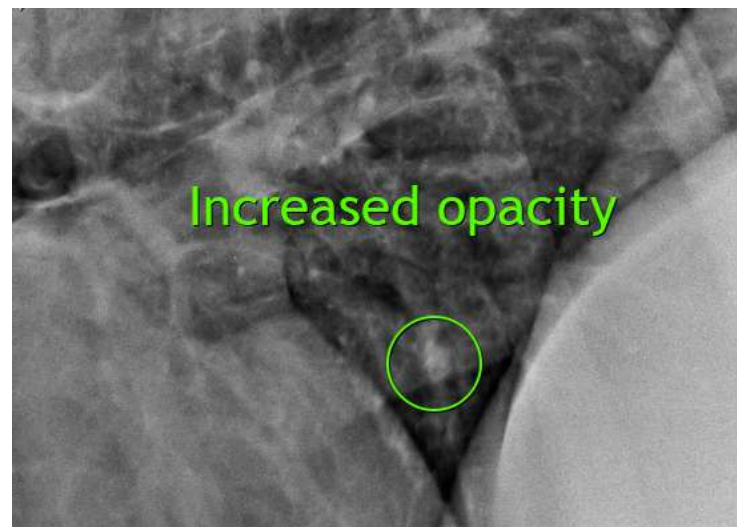
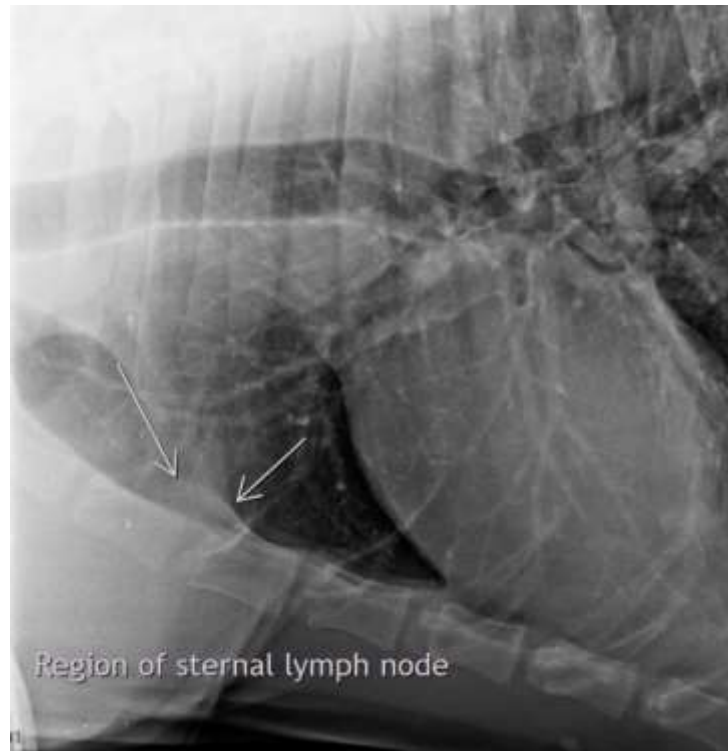
Dr. Coe Lindner

INVOICE

49386

DATE

1-7-22





PATIENT

King Irwin

The information and recommendations provided are based on the images presented by the referring veterinarian. No evaluation can be communicated regarding pathology that was not visible in the image/video clips provided.

SPECIES

Canine

Thank you for this referral. If the clinical or image interpretation does not parallel your findings or if I can be of any further assistance please contact me.

BREED

Great Dane

Heike Rudolf, DVM, Dr. med. vet., DipECVDI, DVR
Dr.H.Rudorf@gmail.com

SEX

Male

AGE

8 Years, 4 Months

INTERPRETED BY

Heike Rudolf, DVM,
Dr. med. Vet.,
DipECVDI DVR

HOSPITAL NAME

All Creatures Animal
Hospital of South Hill,
Inc.

REFERRING VET

Dr. Coe Lindner

INVOICE

49386

DATE

1-7-22