



PATIENT PRESENTING CLINICAL SIGNS

PATIENT Rocky Pettinato
PRESENTING CLINICAL SIGNS History: Patient has been lame on/off on right hind since Aug '22. Patient has trouble getting up & using stairs. Unsure if patient sustained injury while playing w/ late housemate. Currently on fish oil, f/t & hw prev, and cosequin sid.

SPECIES Abnormal PE/Chem/CBC/UA Results: Right stifle mild crepitus- elicited pain response; left stifle mild crepitus. No drawer sign bilaterally. 4DX negative x 4 today.
SPECIES Canine

RADIOGRAPHIC STUDY OF THE STIFLES

BREED The muscle mass of both legs is reduced, especially around the femora.

BREED Hound Mix
 All bones are well mineralized, have a normal trabecular structure and a smooth surface. Cortical-medullary development and differentiation of the long bones are physiological.

SEX Both stifle joints have smooth subchondral bone surfaces, and the centre of the femoral condyles is in line with the intercondylar eminence. The cranial fat pad is markedly reduced, especially on the right leg. Small, calcified specks are just visible in the cranial joint space. The caudal fascial plains are obliterated. New bone formation is present on the femoral ridges, condyles, fabellae, distal pole of the patellae and tibial plateau (especially at the tibial insertion of the cranial cruciate ligament).
SEX Neutered Male

AGE

5 Years

RADIOGRAPHIC DIAGNOSIS

Bilateral

INTERPRETED BY

- Joint effusion/fibrosis
- Osteoarthritis
- Muscle atrophy

Heike Rudolf, DVM,
 Dr. med. Vet.,
 DipECVDI DVR

INTERPRETATION OF THE FINDINGS & FURTHER RECOMMENDATIONS

The changes are compatible with cruciate ligament disease. This may be due to a partial rupture of the cruciate ligaments with ensuing fibrosis to stabilize the joints. The poor muscle development suggests a long-standing problem with reduced physical activity. Surgery should be considered.

HOSPITAL NAME

Pocono Peak VC

REFERRING VET

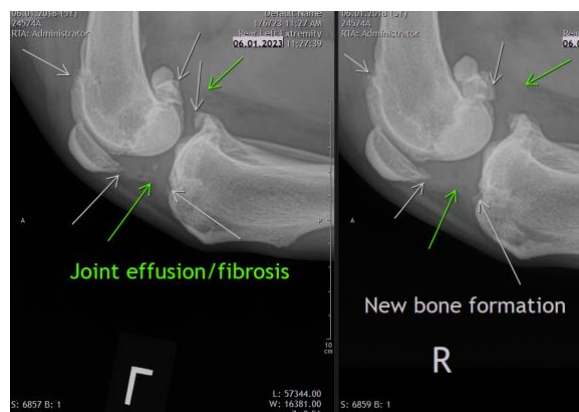
Dr. Nicole Norris-Carney

INVOICE

20453

DATE

1/6/23





PATIENT

Rocky Pettinato

The information and recommendations provided are based on the images presented by the referring veterinarian/sonographer. No evaluation can be communicated regarding pathology that was not visible in the image/video clips provided.

SPECIES

Canine

Thank you for this referral. If the clinical or image interpretation does not parallel your findings or if I can be of any further assistance please contact me.

Heike Rudorf, DVM, Dr. med. vet., DipECVDI, DVR
dr.h.rudorf@gmail.com

BREED

Hound Mix

SEX

Neutered Male

AGE

5 Years

INTERPRETED BY

Heike Rudorf, DVM,
Dr. med. Vet.,
DipECVDI DVR

HOSPITAL NAME

Pocono Peak VC

REFERRING VET

Dr. Nicole Norris-
Carney

INVOICE

20453

DATE

1/6/23