



PATIENT PRESENTING CLINICAL SIGNS

Nestor Pitkin History: Eating less
 Abnormal PE/Chem/CBC/UA Results: Mildly anemic, mildly elevated reticulocytes, rest WNL

SPECIES RADIOGRAPHIC STUDY OF THE ABDOMEN

Feline The body condition score is 8/9 with smooth alternating layers of fat and soft tissue opacity.

BREED The bony structures are within normal limits.

DSH The abdominal detail is good; diaphragm and abdominal wall are intact.

The liver is located within the costal arch and the caudo-ventral lobe is pointed.

SEX The spleen is small with a physiological shape.

Neutered Male The stomach on the VD view appears to be large and filled with a mixture of soft tissue and gas opacity. Distribution and size of the small intestinal loops appear physiological. Colon and rectum contain some fecal matter.

AGE 12 Years Both renal shadows have a physiological size, shape and opacity; the surfaces are smooth. The bladder is located in the abdominal cavity and contains a moderate amount of homogeneous fluid opacity.

INTERPRETED BY The sublumbar region appears physiological.

RADIOGRAPHIC DIAGNOSIS

- Full fundus
- Obesity

Heike Rudolf, DVM,
 Dr. med. Vet.,
 DipECVDI DVR

HOSPITAL NAME INTERPRETATION OF THE FINDINGS & FURTHER RECOMMENDATIONS

St. Catharine's AH Elevated reticulocytes in anemic cats are a sign of bleeding disorders. Free abdominal fluid is not present in these images. Fecal samples should be obtained to rule out parasitic infestation. If the anemia is severe, stomach as well as duodenum assessed for ulcerations (gastro-duodenoscopy). Blood should be obtained for full biochemistry to rule out renal failure, if it has not already been done.

REFERRING VET

Dr. Jui Gokhale

INVOICE

20451

DATE

1/6/23



PATIENT

Nestor Pitkin

SPECIES

Feline

BREED

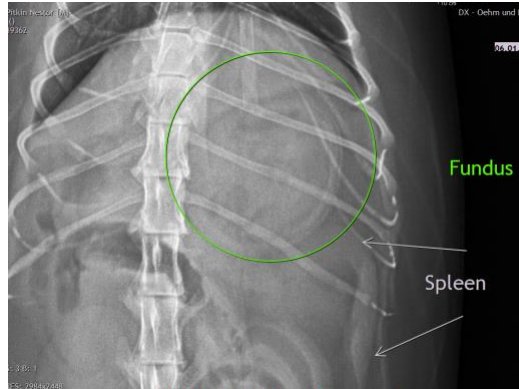
DSH

SEX

Neutered Male

AGE

12 Years



The information and recommendations provided are based on the images presented by the referring veterinarian/sonographer. No evaluation can be communicated regarding pathology that was not visible in the image/video clips provided.

SEX

Thank you for this referral. If the clinical or image interpretation does not parallel your findings or if I can be of any further assistance please contact me.

AGE

Heike Rudolf, DVM, Dr. med. vet., DipECVDI, DVR
dr.h.rudorf@gmail.com

12 Years

INTERPRETED BY

Heike Rudolf, DVM,
Dr. med. Vet.,
DipECVDI DVR

HOSPITAL NAME

St. Catharine's AH

REFERRING VET

Dr. Jui Gokhale

INVOICE

20451

DATE

1/6/23