



PATIENT PRESENTING CLINICAL SIGNS

Miles Mallory History: History of intermittent coughing at night for past few months. Started with 1 coughing fit every few nights and has progressed to 1 coughing fit every night. Eating and drinking normally. Intermittent vomiting (chronic). Slight wheeze auscultated in lung fields. Remainder of physical exam other than obesity and overgroomed abdomen unremarkable.

SPECIES

Feline Abnormal PE/Chem/CBC/UA Results: Chemistry/CBC pending

RADIOGRAPHIC STUDY OF THE THORAX

BREED

The body condition score is 9/9 with smooth alternating layers of fat and soft tissue opacity.

DSH

The bony structures appear physiological.

SEX

The lungs are in contact with the thoracic boundaries and the tips are pointed. The lobar vessels are visible. The bronchial tree shows calcified walls which are slightly tortuous in the main bronchi for the cranial lobes. Doughnuts and tramlines are present. The degree of pulmonary expansion is fair.

Neutered Male

The cranial mediastinum is of physiological size and opacity. The trachea diverges from the thoracic vertebrae and dips at the carina.

AGE

The cardiac silhouette occupies 75% of the chest height and 2 intercostal spaces. No chamber or outflow tract enlargement is evident.

15 Years 6 Months

RADIOGRAPHIC DIAGNOSIS

- Bronchial pattern

INTERPRETED BY

INTERPRETATION OF THE FINDINGS & FURTHER RECOMMENDATIONS

**Heike Rudolf, DVM,
Dr. med. Vet.,
DipECVDI DVR**

The changes are compatible with bronchitis which can be due to peribronchial infiltrate with eosinophils or lymphocytes and granulocytes. Tracheobronchoscopy with broncho-alveolar lavage is needed for a definitive diagnosis. Both types of infiltrate can occur simultaneously, thus sole treatment with corticosteroids without a definitive diagnosis is not recommended. Obesity is known to worsen clinical signs of cough and impair lung function; weight control is strongly recommended.

HOSPITAL NAME

Gentle Doctor AH

REFERRING VET

Dr. Thorson

INVOICE

20450

DATE

1/6/23



PATIENT

Miles Mallory

SPECIES

Feline

BREED

DSH

SEX

Neutered Male

AGE

15 Years 6 Months

INTERPRETED BY

Heike Rudolf, DVM,
Dr. med. Vet.,
DipECVDI DVR

HOSPITAL NAME

Gentle Doctor AH

REFERRING VET

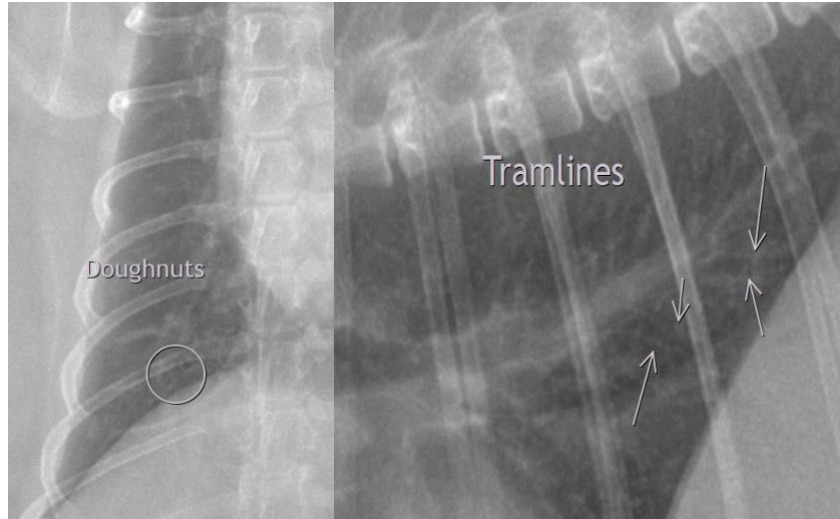
Dr. Thorson

INVOICE

20450

DATE

1/6/23



The information and recommendations provided are based on the images presented by the referring veterinarian/sonographer. No evaluation can be communicated regarding pathology that was not visible in the image/video clips provided.

Thank you for this referral. If the clinical or image interpretation does not parallel your findings or if I can be of any further assistance please contact me.

Heike Rudolf, DVM, Dr. med. vet., DipECVDI, DVR
dr.h.rudorf@gmail.com