



PATIENT PRESENTING CLINICAL SIGNS

Yavrik Caglaya History: P hurt front left leg on 12/24/21 and O said P was not able to put any type of pressure on leg but ever since that day P has gotten better. P could apply moderate pressure on leg. Other than that incident P is still playful and doing well.

SPECIES RADIOGRAPHIC STUDY OF THE CARPI

Feline

A mildly overriding spiral fracture with is present in the mid diaphysis of the humerus. The fracture ends appear to be pointed. Multiple, small bone fragments are evident on the distal aspect of the proximal fracture tip. The fracture ends are beginning to round off.

BREED

DSH

Digit one shows a large metacarpus (MC). P2 and P3 are located medial to P1 and soft tissue swelling is present lateral to the nail. All bony ends are smooth.

SEX RADIOGRAPHIC DIAGNOSIS

Female

- Spiral fracture humerus
- Fully formed MC1
- Digit 1: separation of P1 from P2 and 3

AGE

8 Months

INTERPRETATION OF THE FINDINGS & FURTHER RECOMMENDATIONS

The humeral fracture is compatible with an incident 10-14 days ago, whereas the digital pathology appears to be older. It is possible that the digital abnormality is congenital. A differential diagnosis is an old fracture or luxation. Obtaining a view of the other paw might help decide on the congenital nature of the lesion. Otherwise, a CT examination can give more detail. However, I feel the humeral fracture is the reason for the acute lameness.

INTERPRETED BY

Heike Rudolf, DVM,
Dr. med. Vet.,
DipECVDI DVR

HOSPITAL NAME

Animal Paradise H

REFERRING VET

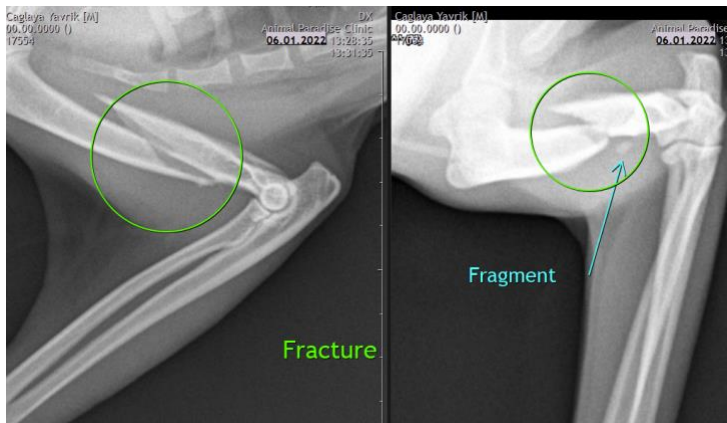
Dr. Elshafie

INVOICE

13284

DATE

1/6/22



The information and recommendations provided are based on the images presented by the referring veterinarian. No evaluation can be communicated regarding pathology that was not visible in the image/video clips provided.



PATIENT

Yavrik Caglaya

Thank you for this referral. If the clinical or image interpretation does not parallel your findings or if I can be of any further assistance please contact me.

SPECIES

Feline

Heike Rudolf, DVM, Dr. med. vet., DipECVDI, DVR
dr.h.rudorf@gmail.com

BREED

DSH

SEX

Female

AGE

8 Months

INTERPRETED BY

Heike Rudolf, DVM,
Dr. med. Vet.,
DipECVDI DVR

HOSPITAL NAME

Animal Paradise H

REFERRING VET

Dr. Elshafie

INVOICE

13284

DATE

1/6/22