



PATIENT PRESENTING CLINICAL SIGNS

Layla Scott History: THE CAUDAL MAMMARY IS SWOLLEN, CONFIRMATION OF FREE THORAX AND ABDOMEN OF METASTATIC DISEASE IS NEEDED BEFORE MASTECTOMY

SPECIES RADIOGRAPH OF THORAX AND ABDOMEN

Canine The body condition score is 7/9 with a large amount of fat dorsal to the sacrum.

A spur of new bone is present on the cranial endplate of T13

BREED

Boxer Mix

Thorax

The degree of pulmonary expansion is fair. The visible lungs are in contact with the thoracic boundaries and the tips are pointed. The lobar vessels are clearly visible to the tertiary branches.

SEX

Spayed Female

The cranial mediastinum is of physiological size and opacity. The trachea diverges from the thoracic vertebrae and the carina is located at T5.

AGE

7 Years

The cardiac silhouette occupies 75% of the chest height and 3 intercostal spaces. No chamber enlargement is evident.

Abdomen

INTERPRETED BY

The abdominal detail is good; diaphragm and abdominal wall are intact.

Heike Rudolf, DVM,
Dr. med. Vet.,
DipECVDI DVR

The liver is located well within the costal arch and the caudo-ventral lobe is pointed.

The tail of the spleen appears physiological.

HOSPITAL NAME

St. Catharine's AH

The gastric axis is cranially rotated, and the stomach is moderately filled with food; the small intestinal loops have a physiological distribution and size. Colon and rectum contain a moderate amount of gas and some fecal matter.

REFERRING VET

Dr. Boctor

One physiological renal shadow is just visible on the LLR view. The bladder is located in the abdominal cavity and contains a small amount of homogeneous fluid opacity.

The sublumbar region appears physiological.

RADIOGRAPHIC DIAGNOSIS

INVOICE

13290

- Smallish liver
- Spondylosis, mild (incidental finding)

INTERPRETATION OF THE FINDINGS & FURTHER RECOMMENDATIONS

DATE

1/6/22



PATIENT

Layla Scott

I can see not pulmonary nodules in the unobscured lung field. For the detection of small lung nodules and mediastinal lymphadenomegaly a CT examination is recommended. The significance of the smallish liver is questionable, but a liver profile should be obtained.

SPECIES

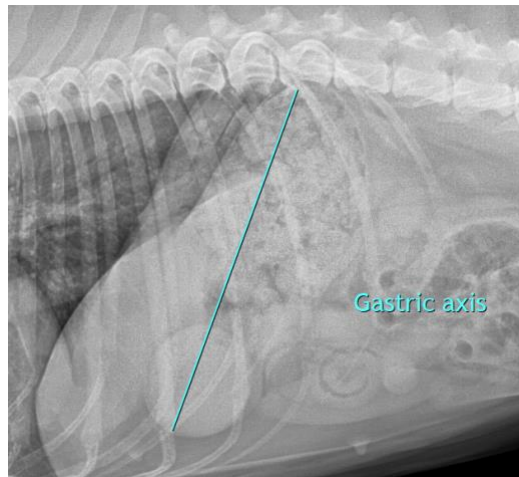
Canine

BREED

Boxer Mix

SEX

Spayed Female



AGE

7 Years

The information and recommendations provided are based on the images presented by the referring veterinarian. No evaluation can be communicated regarding pathology that was not visible in the image/video clips provided.

INTERPRETED BY

Heike Rudolf, DVM,
Dr. med. Vet.,
DipECVDI DVR

Thank you for this referral. If the clinical or image interpretation does not parallel your findings or if I can be of any further assistance please contact me.

Heike Rudolf, DVM, Dr. med. vet., DipECVDI, DVR
dr.h.rudorf@gmail.com

HOSPITAL NAME

St. Catharine's AH

REFERRING VET

Dr. Boctor

INVOICE

13290

DATE

1/6/22