



PATIENT

Poppy Deeley

SPECIES

Canine

BREED

Dachshund

SEX

Spayed Female

AGE

10 Years

WEIGHT

4.5 kg

INTERPRETED BY

Heike Rudorf, DVM, Dr.
med. Vet., DipECVDI
DVR

IMAGING PERFORMED BY

Chappelle VC

HOSPITAL NAME

Chappelle VC

REFERRING VET

Dr. Bassam
Abdelmalek

INVOICE

35629

DATE

1/30/26

PRESENTING CLINICAL SIGNS

History: vomited yesterday, seem to be short of breath/ difficulty breathing

Abnormal PE/Chem/CBC/UA Results: blood work normal

RADIOGRAPHIC STUDY OF THE THORAX

The body condition score is 6/9 with smooth, alternating layers of fat and soft tissue opacity.

The bony structures appear physiological.

The cranial mediastinum is of physiologic size and opacity. The trachea runs parallel to the thoracic vertebrae, and the carina is level with it.

The degree of pulmonary expansion is fair. The lung lobes extend to the thoracic boundaries. An alveolar infiltrate with air-bronchograms is present in both caudo-dorsal lung lobes. The ventral pulmonary vessels are well outlined to the tertiary branches.

The cardiac silhouette occupies 85% of the chest height and 3 intercostal spaces (VHS= 10). The caudal heart border is straight; a small bulge located to the left of the aortic arch.

RADIOGRAPHIC DIAGNOSIS

- Alveolar infiltrate both caudo-dorsal lobes
- Possible left sided cardiomegaly

INTERPRETATION OF THE FINDINGS & FURTHER RECOMMENDATIONS

An interstitial lung pattern is a non-specific finding and accentuated by the only fair expansion of the lung field. Possible differential diagnoses for a bilateral alveolar infiltrate include:

- Infection (bacterial, fungal e.g., candida, viral, Rickettsia, Spirochetes, parasitic e.g., angiostrongylus)
- Edema
- Inflammation (eosinophilic bronchopneumopathy, smoke inhalation)
- Hemorrhage

Fecal samples should be obtained to rule out parasites. Bronchoscopy with broncho-alveolar lavage is recommended; samples should be submitted for bacteriological and cytological examination. To rule out mitral insufficiency and Cor pulmonale, echocardiography is recommended.



PATIENT

Poppy Deeley

SPECIES

Canine

BREED

Dachshund

SEX

Spayed Female

AGE

10 Years

WEIGHT

4.5 kg

INTERPRETED BY

Heike Rudorf, DVM, Dr.
med. Vet., DipECVDI
DVR

IMAGING PERFORMED BY

Chappelle VC

HOSPITAL NAME

Chappelle VC

REFERRING VET

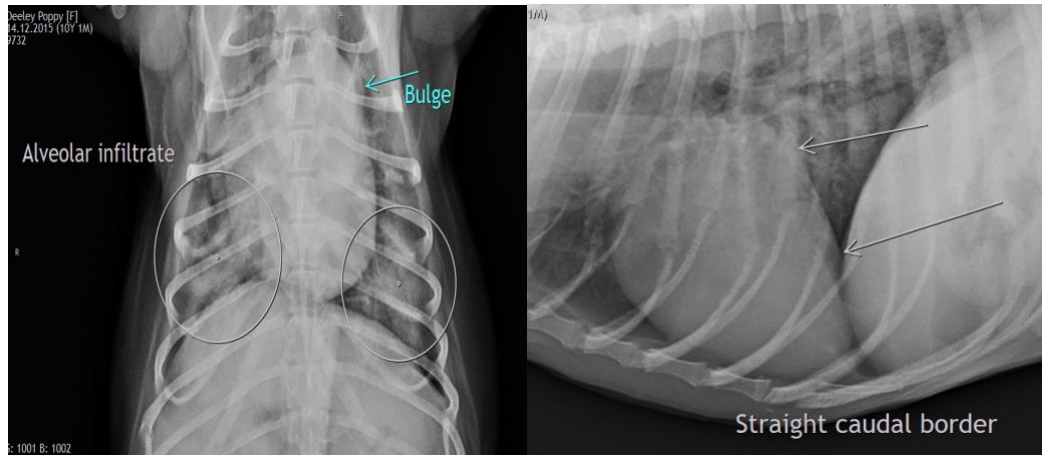
Dr. Bassam
Abdelmalek

INVOICE

35629

DATE

1/30/26



The information and recommendations provided are based on the images presented by the referring veterinarian/sonographer. No evaluation can be communicated regarding pathology that was not visible in the image/video clips provided.

Thank you for this referral. If the clinical or image interpretation does not parallel your findings or if I can be of any further assistance, please contact me.

Heike Rudorf, DVM, Dr. med. vet., DipECVDI, DVR
info@sonopath.com