



PATIENT

Foxie Parsons

SPECIES

Feline

BREED

DSH

SEX

Spayed Female

AGE

14 Years

WEIGHT

5.2 Pounds

INTERPRETED BY

Heike Rudorf, DVM, Dr.
med. Vet., DipECVDI
DVR

IMAGING PERFORMED BY

Dr. Christopher Dewitt

HOSPITAL NAME

Williamsburg VC

REFERRING VET

Dr. Christopher Dewitt

INVOICE

35627

DATE

1/30/26

PRESENTING CLINICAL SIGNS

History: P has a history of hyperthyroidism and is being referred to Radiocat for I-131 therapy. P has been off methimazole for a week to prepare for treatment.

Abnormal PE/Chem/CBC/UA Results: weight loss elevated blood pressure hyperthyroidism

RADIOGRAPHIC STUDY OF THE THORAX

The body condition score is 4-5/9; the skin outlines the dorsal spinous processes

New bone formation surrounds the elbow joints.

The cranial mediastinum is of physiologic size and opacity. The trachea diverges from the thoracic vertebrae, and the carina is located level with T5/6.

The degree of pulmonary expansion is very good. The lung lobes are well aerated and extend to the thoracic boundaries. Pulmonary vessels are well outlined to the tertiary branches. The bronchial tree is thin walled and tapers towards the periphery.

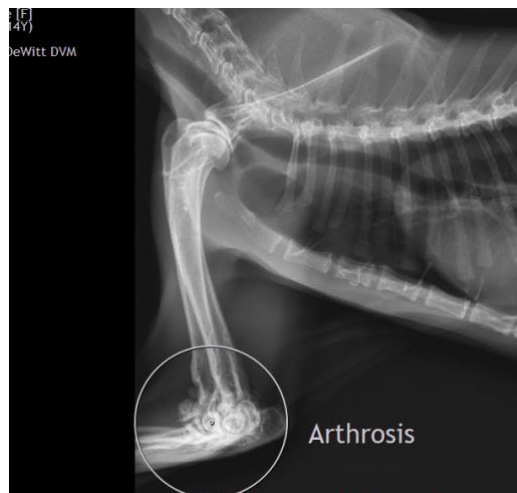The cardiac silhouette is tilted forward; it thus occupies 65% of the chest height and 2 intercostal spaces. Chamber or outflow tract enlargement is not obvious.

RADIOGRAPHIC DIAGNOSIS

- Elbow arthrosis, bilat.

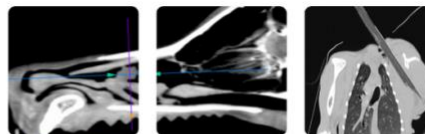
INTERPRETATION OF THE FINDINGS & FURTHER RECOMMENDATIONS

I can see no thoracic mass. The cardiac shape appears physiological however, echocardiography is recommended in cases of hyperthyroidism to rule out localized HCM. Checking the aortic trifurcation with color flow can help identify early thrombus formation.



The information and recommendations provided are based on the images presented by the referring veterinarian/sonographer. No evaluation can be communicated regarding pathology that was not visible in the image/video clips provided.

Thank you for this referral. If the clinical or image interpretation does not parallel your findings or if I



PATIENT

can be of any further assistance, please contact me.

Foxie Parsons

Heike Rudorf, DVM, Dr. med. vet., DipECVDI, DVR
info@sonopath.com

SPECIES

Feline

BREED

DSH

SEX

Spayed Female

AGE

14 Years

WEIGHT

5.2 Pounds

INTERPRETED BY

Heike Rudorf, DVM, Dr.
med. Vet., DipECVDI
DVR

**IMAGING
PERFORMED BY**

Dr. Christopher Dewitt

HOSPITAL NAME

Williamsburg VC

REFERRING VET

Dr. Christopher Dewitt

INVOICE

35627

DATE

1/30/26