



**PATIENT PRESENTING CLINICAL SIGNS**

Marty Vonderlage History: Six-month history of dry, non-productive cough. On auscultation can hear audible clicking/popping noise. Caudal left lung field abnormal on x-ray

**SPECIES RADIOGRAPHIC STUDY OF THE THORAX**

Feline The body condition score is 9/9 with smooth alternating layers of fat and soft tissue opacity. New bon is present in both elbow joints.

**BREED** The degree of pulmonary expansion is fair. A cavitating mass is located in the left caudo-ventral lobe and obscures the caudal left heart border. The main caudal lobar bronchus is not evident and the bronchus for the caudal aspect of the cranial left lobe is cranially displaced. The lobar vessels in the other of the lung fields are slightly blurred in the periphery and mild bronchial wall thickening is present.

**SEX** The cranial mediastinum appears physiological.

Neutered Male The cardiac silhouette occupies 75% of the chest height and 2.5 intercostal spaces. No chamber or outflow tract enlargement is evident.

**AGE RADIOGRAPHIC DIAGNOSIS**

17 Years 1 Month

- Cavitary lesion left caudal lobe

Incidental findings

**INTERPRETED BY**

- Obesity
- Elbow OA

Heike Rudorf, DVM,  
Dr. med. Vet.,  
DipECVDI DVR

**INTERPRETATION OF THE FINDINGS & FURTHER RECOMMENDATIONS**

**HOSPITAL NAME** A space cavitating lesion in an old cat is most likely due to a tumor such as adenocarcinoma or bronchial carcinoma. However, abscess has to be considered. The mass is in close contact with the left rib cage and obtaining an ultrasound guided sample is thus possible. A CT examination would be necessary to identify lymphadenopathy and small nodular changes.

Gentle Doctor AH

**REFERRING VET** Obesity is known to worsen clinical signs of cough and impair lung function; weight control is strongly recommended.

Dr. Sergio Valadez

**INVOICE**

13668

**DATE**

1/28/22



**PATIENT**

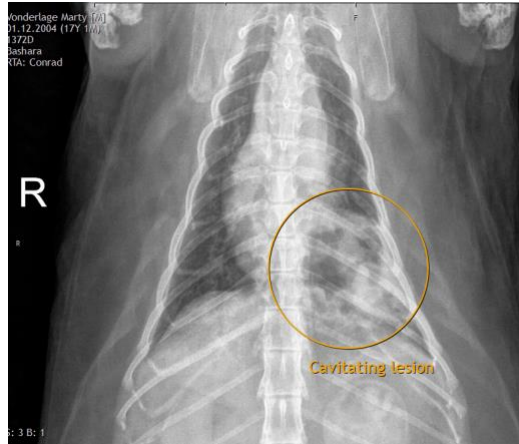
Marty Vonderlage

**SPECIES**

Feline

**BREED**

DSH



**SEX**

Neutered Male

**AGE**

17 Years 1 Month

**The information and recommendations provided are based on the images presented by the referring veterinarian/sonographer. No evaluation can be communicated regarding pathology that was not visible in the image/video clips provided.**

Thank you for this referral. If the clinical or image interpretation does not parallel your findings or if I can be of any further assistance please contact me.

**Heike Rudolf**, DVM, Dr. med. vet., DipECVDI, DVR  
dr.h.rudorf@gmail.com

**INTERPRETED BY**

Heike Rudolf, DVM,  
Dr. med. Vet.,  
DipECVDI DVR

**HOSPITAL NAME**

Gentle Doctor AH

**REFERRING VET**

Dr. Sergio Valadez

**INVOICE**

13668

**DATE**

1/28/22