



**PATIENT PRESENTING CLINICAL SIGNS**

**Betty Haynes** History: Last week Betty hurt her L front foot. She started out limping periodically for 1 week and in the last 3 days she has not been putting any weight on her L front. She has been chewing at her paw on and off. Lou did not feel or see anything when she looked at the paw.

**SPECIES**

**Feline** Abnormal PE/Chem/CBC/UA Results: RESENTMENT OF PALPATION OF RIGHT FRONT FROM DISTAL ANTEBRACHIUM TO FOOT. NOTHING ABNORMAL FELT IN ANY LIMB. Ambulatory X 4, NERVOUS AND CROUCHED GAIT BUT NOT LIMPING. SITS WITH NORMAL WT DISTRIBUTION HERE. Neck, spine, and tail are normal. No pain shown during exam or x-rays.

**BREED**

**American Tabby**

**RADIOGRAPHIC STUDY OF THE ELBOWS AND CARPI**

The muscle mass caudal to the humerus and on the medial aspect of the antebrachium is slightly reduced on the left.

**SEX**

**Spayed Female**

The bones are well mineralized, have a normal trabecular structure and smooth, continuous surfaces. Cortical-medullary development and differentiation of the long bones are physiological.

**AGE**

**3 Years 6 Months**

The joints appear congruent with even subchondral bone surfaces. The digits of both paws are equidistantly spaced, and the sesamoid bones are physiological.

**RADIOGRAPHIC DIAGNOSIS**

- Muscle atrophy left limb, mild

**INTERPRETED BY**

**Heike Rudorf, DVM,  
Dr. med. Vet.,  
DipECVDI DVR**

**INTERPRETATION OF THE FINDINGS & FURTHER RECOMMENDATIONS**

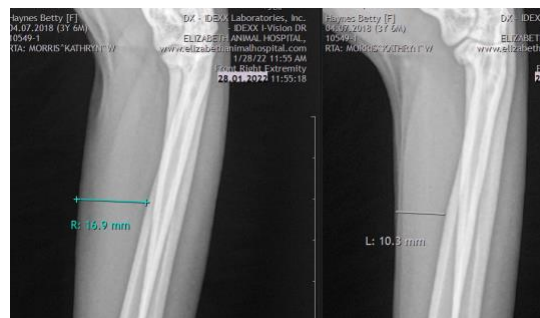
I can see no changes that would explain the clinical signs described by the owner. The mild muscle atrophy may be an artefact but using a tape measure will help identify the correct maximal circumference. Should this indeed be reduced, soft tissue injuries such as flexor myositis or tendinitis can be ruled out with contrast CT or MRI. However, if the animal is responding to conservative management, further imaging can be postponed.

**HOSPITAL NAME**

**Elizabeth AH**

**REFERRING VET**

**Dr. Leon Anderson**



**INVOICE**

**13766**

**DATE**

**1/28/22**



**PATIENT**

Betty Haynes

**The information and recommendations provided are based on the images presented by the referring veterinarian/sonographer. No evaluation can be communicated regarding pathology that was not visible in the image/video clips provided.**

**SPECIES**

Feline

Thank you for this referral. If the clinical or image interpretation does not parallel your findings or if I can be of any further assistance please contact me.

**Heike Rudolf**, DVM, Dr. med. vet., DipECVDI, DVR  
dr.h.rudorf@gmail.com

**BREED**

American Tabby

**SEX**

Spayed Female

**AGE**

3 Years 6 Months

**INTERPRETED BY**

Heike Rudolf, DVM,  
Dr. med. Vet.,  
DipECVDI DVR

**HOSPITAL NAME**

Elizabeth AH

**REFERRING VET**

Dr. Leon Anderson

**INVOICE**

13766

**DATE**

1/28/22