



PATIENT PRESENTING CLINICAL SIGNS

Bella Jadavji History: Vomiting since 4 am twice and continued vomiting until 9 am. Diarrhea developed as well. Likes to chew on stuff, not sure of dietary indiscretion. Abnormal PE/Chem/CBC/UA Results: Tense abdomen.

SPECIES RADIOGRAPHIC STUDY OF THE ABDOMEN

Canine
The body condition score (BCS) is 4/9.

BREED Skeletal immaturity compatible with the given age is noted.

Bichon Frise Mix **Abdomen**

The abdominal detail is in line with the low BCS; diaphragm and abdominal wall are intact.

SEX The gastric fundus is outlined by air and the rugae appear thick and net-like; the gastric axis is slightly rotated cranially. The small intestinal loops appear plump, contain fluid and have a homogeneous size and physiological distribution. The cecum is large and contains unformed feces as well as gas. Colon and rectum contain a moderate amount of gas.

AGE Both renal shadows have a physiological size, shape and opacity; the surfaces are smooth. All other outlined structures appear physiological.

6 Months

RADIOGRAPHIC DIAGNOSIS

INTERPRETED BY

- Large cecum
- Possible gastritis

Heike Rudorf, DVM,
Dr. med. Vet.,
DipECVDI DVR

INTERPRETATION OF THE FINDINGS & FURTHER RECOMMENDATIONS

HOSPITAL NAME

The clinical signs are most likely the result of a viral infection. In case conservative treatment including i.v. fluids and antiemetics has not improved the clinical signs, a repeat VD view is recommended to compare size and contents of the cecum. Barium can be given to sooth the gastric mucosa which will help reduce the vomiting.

Truscott AH

REFERRING VET

Dr. Erini Abraham

INVOICE

13679

DATE

1/28/22



PATIENT

Bella Jadavji

SPECIES

Canine

BREED

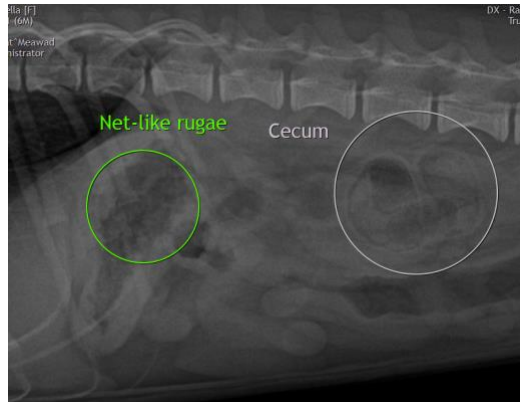
Bichon Frise Mix

SEX

Spayed Female

AGE

6 Months



The information and recommendations provided are based on the images presented by the referring veterinarian/sonographer. No evaluation can be communicated regarding pathology that was not visible in the image/video clips provided.

Thank you for this referral. If the clinical or image interpretation does not parallel your findings or if I can be of any further assistance please contact me.

Heike Rudorf, DVM, Dr. med. vet., DipECVDI, DVR
dr.h.rudorf@gmail.com

INTERPRETED BY

Heike Rudorf, DVM,
Dr. med. Vet.,
DipECVDI DVR

HOSPITAL NAME

Truscott AH

REFERRING VET

Dr. Erini Abraham

INVOICE

13679

DATE

1/28/22