



PATIENT PRESENTING CLINICAL SIGNS

Leo Massey History: Lameness, o thinks bilaterally, but left for sure
 Abnormal PE/Chem/CBC/UA Results: MPL grade 1 is detected bilaterally. Positive cranial compression test equivocal bilateral.

SPECIES RADIOGRAPHIC STUDY OF THE STIFLES

Canine The caudal thigh muscle mass is reduced by 0.5cm.

BREED Both stifle joints have smooth subchondral bone surfaces, and the centre of the femoral condyles is in line with the intercondylar eminence.

Mixed Right stifle: the fat is slightly cranially displaced by a slightly irregular soft tissue opacity within the joint. A small amount of new bone formation is present on the distal pole of the patella and one fabella.

SEX

Neutered Male All bones are well mineralized, have a normal trabecular structure and a smooth surface. Cortical-medullary development and differentiation of the long bones are physiological.

AGE RADIOGRAPHIC DIAGNOSIS

5 Years Right stifle

- Effusion, mild
- Arthrosis, mild
- Muscle atrophy, mild

INTERPRETED BY

Heike Rudolf, DVM,
 Dr. med. Vet.,
 DipECVDI DVR

INTERPRETATION OF THE FINDINGS & FURTHER RECOMMENDATIONS

The changes are suggestive of cruciate disease due to a partial rupture. A grade 1 or 2 patella luxation is usually only detected during clinical examination. Assessment of the femoral ridges is possible on a flexed stifle joint with the beam orientated perpendicular to the groove.

HOSPITAL NAME

Friendship Springs VC

REFERRING VET

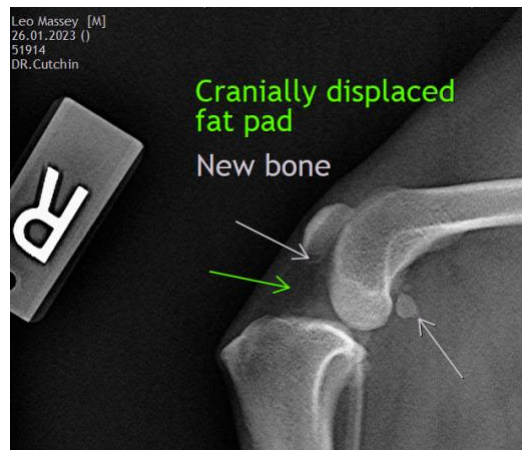
Dr. Trae Cutchin

INVOICE

20821

DATE

1/27/23





PATIENT

Leo Massey

The information and recommendations provided are based on the images presented by the referring veterinarian/sonographer. No evaluation can be communicated regarding pathology that was not visible in the image/video clips provided.

SPECIES

Canine

Thank you for this referral. If the clinical or image interpretation does not parallel your findings or if I can be of any further assistance please contact me.

Heike Rudorf, DVM, Dr. med. vet., DipECVDI, DVR
dr.h.rudorf@gmail.com

BREED

Mixed

SEX

Neutered Male

AGE

5 Years

INTERPRETED BY

Heike Rudorf, DVM,
Dr. med. Vet.,
DipECVDI DVR

HOSPITAL NAME

Friendship Springs VC

REFERRING VET

Dr. Trae Cutchin

INVOICE

20821

DATE

1/27/23