



PATIENT

Hunter DiLullo

PRESENTING CLINICAL SIGNS

Acute lameness jumped off steps yesterday

SPECIES

Canine

RADIOGRAPH OF SHOULDERS AND CARPI

Lateral L elbow including both shoulders, DP L paw, including flexed oblique R paw

BREED

Labrador Retriever

RADIOGRAPHIC FINDINGS

A mild soft tissue swelling is present on the lateral aspect of the L carpus and along digit 5.

SEX

Male Neutered

The shoulder joints appear congruent with even subchondral bone surfaces.

The left elbow joint is congruent with smooth subchondral bone surfaces.

All sesamoid bones are physiological.

AGE

9 Years

RADIOGRAPHIC DIAGNOSIS

- Soft tissue swelling along digit 5 and lateral carpus

INTERPRETED BY

Heike Rudolf, DVM,
Dr. med. Vet.,
DipECVDI DVR

INTERPRETATION OF THE FINDINGS & FURTHER RECOMMENDATIONS

The lameness is likely due to a soft tissue injury and can also affect tendons, joint capsules and muscles. Should conservative treatment bring no results, contrast CT should be considered to rule out muscle and tendon injuries. Ultrasound can be employed to look at the swelling.

HOSPITAL NAME

New Bridge
Veterinary Practice

TECHNICAL COMMENTS

Human bones in DP view

REFERRING VET

Dr. Abina Glennon

INVOICE

49901

DATE

1-27-22



PATIENT

Hunter DiLullo

SPECIES

Canine

BREED

Labrador Retriever

SEX

Male Neutered

AGE

9 Years

INTERPRETED BY

Heike Rudorf, DVM,
Dr. med. Vet.,
DipECVDI DVR

HOSPITAL NAME

New Bridge
Veterinary Practice

REFERRING VET

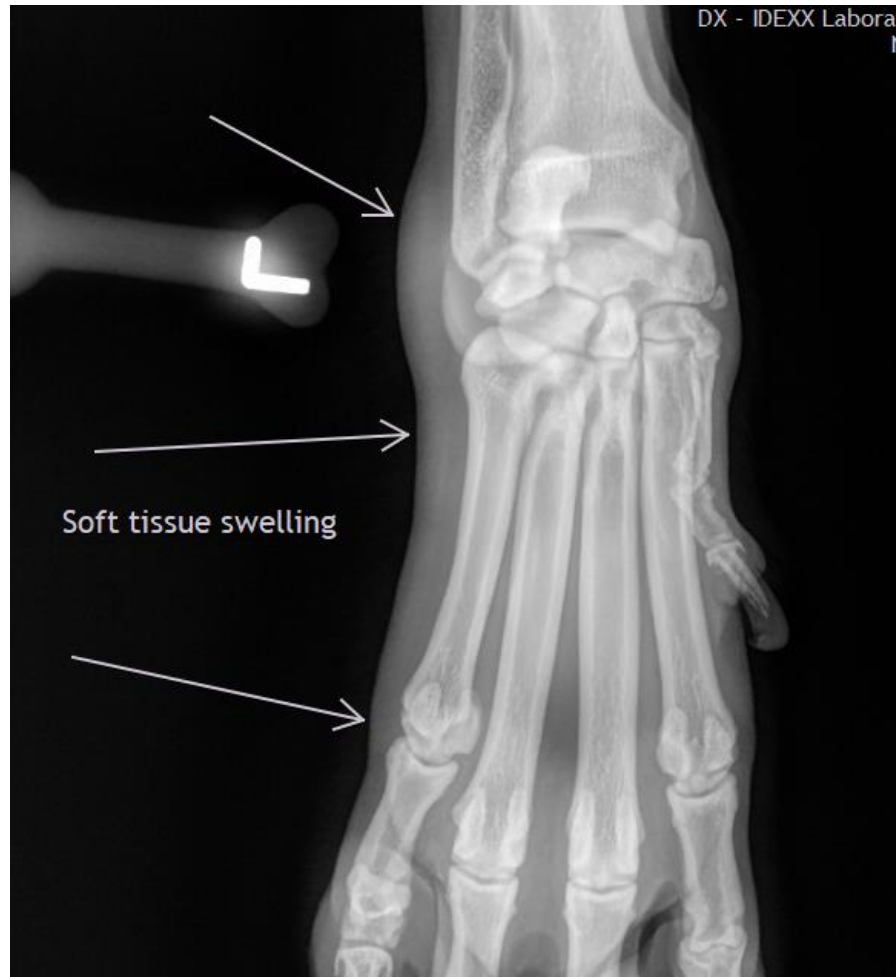
Dr. Abina Glennon

INVOICE

49901

DATE

1-27-22



The information and recommendations provided are based on the images presented by the referring veterinarian/sonographer. No evaluation can be communicated regarding pathology that was not visible in the image/video clips provided.

Thank you for this referral. If the clinical or image interpretation does not parallel your findings or if I can be of any further assistance please contact me.

Heike Rudorf, DVM, Dr. med. vet., DipECVDI, DVR
Dr.H.Rudorf@gmail.com