SonoPath Teleradiology

EDUCATIONAL TELECONSULTATION SERVICES™

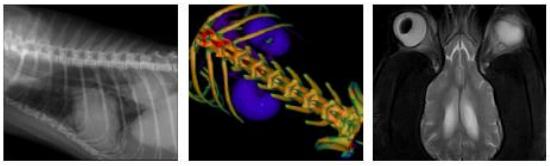

SonoPath.com
1-800-838-4268 info@sonopath.com

**PATIENT**

Abigail Burek

**SPECIES**

Feline

**BREED**

Domestic Long Hair

**SEX**

Spayed Female

**AGE**

13 Years

**INTERPRETED BY**

Heike Rudorf, DVM, Dr. med. Vet., DipECVDI DVR

**HOSPITAL NAME**

Four Corners Veterinary Practice

**REFERRING VET**

Gregory Roccaro

**INVOICE**

49905

**DATE**

1-27-22

## PRESENTING CLINICAL SIGNS

Hyporexia x 5 days. Dehydrated.

## RADIOGRAPH OF THE ABDOMEN

RLR, LLR, VD whole body.

## RADIOGRAPHIC FINDINGS

The body condition score (BCS) is 5/9 with smooth alternating layers of fat and soft tissue opacity.

A small amount of spondylosis is located on the ventral endplate of L6.

The abdominal detail is in line with the low BCS.

The stomach contains a mixture of air, fluid and food. The small intestinal loops have a physiological distribution and size; some contain fluid, others gas. A small amount of mineral opacity is present in two small intestinal loops cranial to the bladder. Colon and rectum contain a moderate amount of formed fecal matter.

The other structures appear physiological.

## RADIOGRAPHIC DIAGNOSIS

- Gastric distension, moderate

## INTERPRETATION OF THE FINDINGS & FURTHER RECOMMENDATIONS

I can see no radiopaque foreign body and the size of the intestinal loops appears homogeneous. The gastric distension could be due to the stress during radiography or could be the result of aerophagia while eating. Abdominal ultrasound is recommended to assess gastro-intestinal wall size and layering, check for triaditis and rule out masses e.g. lymphadenomegaly.

SonoPath Teleradiology

EDUCATIONAL TELECONSULTATION SERVICES™

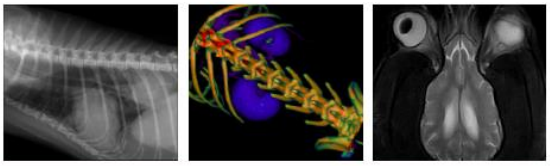

SonoPath.com
1-800-838-4268 info@sonopath.com

**PATIENT**

Abigail Burek

**SPECIES**

Feline

**BREED**

Domestic Long Hair

**SEX**

Spayed Female

**AGE**

13 Years

**INTERPRETED BY**

Heike Rudorf, DVM, Dr. med. Vet., DipECVDI DVR

**HOSPITAL NAME**

Four Corners Veterinary Practice

**REFERRING VET**

Gregory Roccaro

**INVOICE**

49905

**DATE**

1-27-22

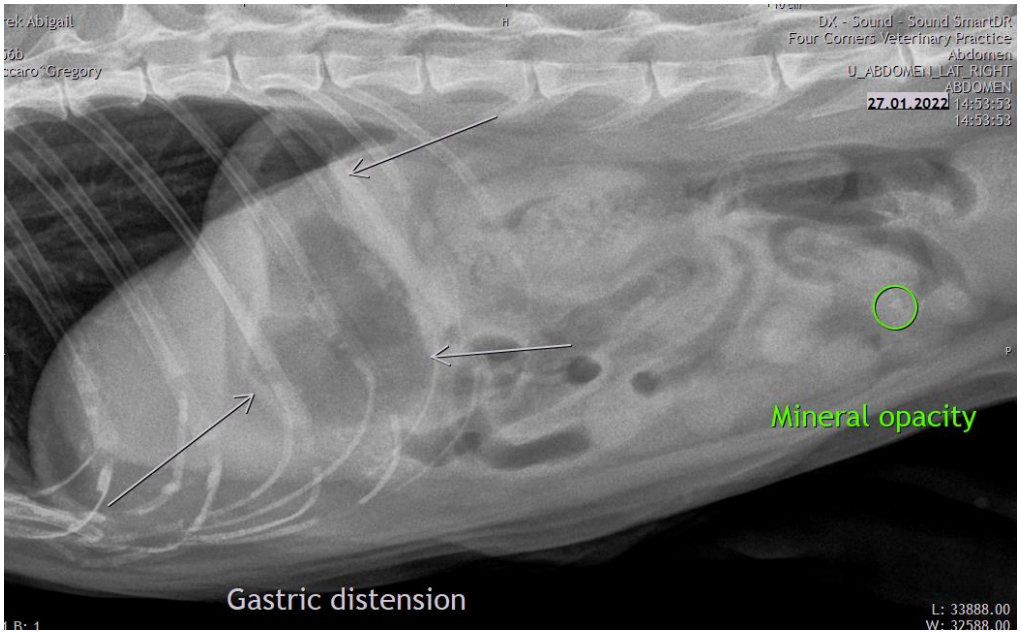


**The information and recommendations provided are based on the images presented by the referring veterinarian/sonographer. No evaluation can be communicated regarding pathology that was not visible in the image/video clips provided.**

Thank you for this referral. If the clinical or image interpretation does not parallel your findings or if I can be of any further assistance please contact me.

**Heike Rudorf**, DVM, Dr. med. vet., DipECVDI, DVR
Dr.H.Rudorf@gmail.com