



**PATIENT PRESENTING CLINICAL SIGNS**

**PATIENT** Solo Pereyra **PRESENTING CLINICAL SIGNS** History: vomiting last three days specially in the morning Owner suspected FB , ate this morning but no vomiting, had history for eating FB before

**SPECIES** Abnormal PE/Chem/CBC/UA Results: Moderate pain , distension was noticed during palpation, Bloodwork including CPLI WNL

**Canine RADIOGRAPHIC STUDY OF THE ABDOMEN**

The body condition score is 6/9 with a slightly tucked up ventral abdominal wall.

**BREED**

**Doberman Pinscher** The bony structures are within normal limits. Skeletal immaturity compatible with the given age is noted.

**SEX**

The abdominal detail is good; diaphragm and abdominal wall are intact.

**Neutered Male**

The liver is located within the costal arch and the caudo-ventral lobe is pointed.

The head of the spleen appears physiological.

**AGE**

**8 Months**

The stomach contains a moderate amount of food; distribution and size of the small intestinal loops appear physiological. The colon contains a moderate amount of unformed fecal matter.

One renal shadow appears of physiological size, shape and opacity; the other is obscured by intestinal loops.

**INTERPRETED BY**

Heike Rudolf, DVM,  
Dr. med. Vet.,  
DipECVDI DVR

**RADIOGRAPHIC DIAGNOSIS**

- Food in stomach
- Feces in colon

**HOSPITAL NAME**

Lakeshore Woods AH

**INTERPRETATION OF THE FINDINGS & FURTHER RECOMMENDATIONS**

I can see no radiopaque foreign object. Viral gastro-enteritis or food indiscretion are the most likely differential diagnoses in the absence of a radiopaque foreign body. Should the dog continue to vomit despite conservative treatment, abdominal ultrasound is recommended to assess wall thickness and layering of the entire GIT; a sliding intussusception may be present if intestinal hypermotility is observed.

**REFERRING VET**

Dr. Sam Masoud

**INVOICE**

20799

**DATE**

1/26/23



**PATIENT**

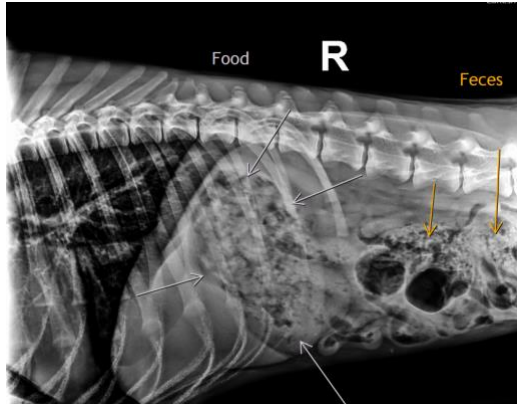
Solo Pereyra

**SPECIES**

Canine

**BREED**

Doberman Pinscher



**SEX**

Neutered Male

**AGE**

8 Months

The information and recommendations provided are based on the images presented by the referring veterinarian/sonographer. No evaluation can be communicated regarding pathology that was not visible in the image/video clips provided.

Thank you for this referral. If the clinical or image interpretation does not parallel your findings or if I can be of any further assistance please contact me.

**Heike Rudorf**, DVM, Dr. med. vet., DipECVDI, DVR  
dr.h.rudorf@gmail.com

**INTERPRETED BY**

Heike Rudorf, DVM,  
Dr. med. Vet.,  
DipECVDI DVR

**HOSPITAL NAME**

Lakeshore Woods AH

**REFERRING VET**

Dr. Sam Masoud

**INVOICE**

20799

**DATE**

1/26/23