



**PATIENT PRESENTING CLINICAL SIGNS**

**Koda Gabriel** History: P has been limping for week and a half right front paw- O states he had this issue 1.5 years ago and it got better with crate rest but this time he is whining and crying and doesn't seem to be getting better.

**SPECIES RADIOGRAPHIC STUDY OF THE CARPI**

**Canine** A soft tissue swelling is located at the radio-carpal joint and appears to be more prominent medially.

**BREED** A small amount of slightly irregular new bone (NB) formation is located on the dorsal aspect of the radio-carpal bone.

Labrador Retriever

**RADIOGRAPHIC DIAGNOSIS**

**SEX** Right carpus

- Neutered Male**
- Soft tissue swelling radio-carpal joint
  - NB radio-carpal bone, mild

**INTERPRETATION OF THE FINDINGS & FURTHER RECOMMENDATIONS**

**AGE** 2 Years

The soft tissue swelling could be the result of an injury to the tendon of the M. abductor digitus 1 longus. In case of chronicity new bone can form around it and a radiographically visible bone tunnel will form. However, I cannot rule out a hairline fissure of the distal radius or one of the carpal bones. The best way to rule this out is a CT examination. On the post contrast examination, the region of the tendon for digit 1 may enhance in the late phase. The new bone on the radio-carpal bone is most likely traumatic in origin which can be either acute, from a previous injury, or chronic.

**INTERPRETED BY**

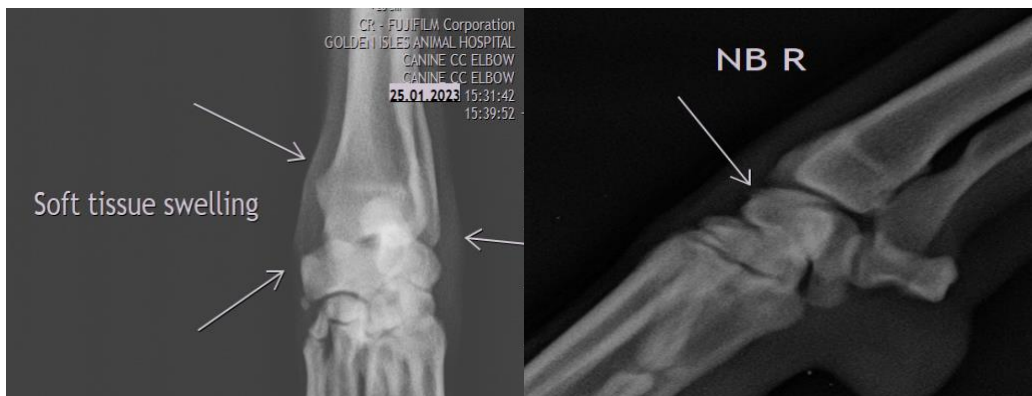
Heike Rudolf, DVM,  
Dr. med. Vet.,  
DipECVDI DVR

**HOSPITAL NAME**

Golden Isles AH

**REFERRING VET**

James Hornbuckle



**INVOICE**

20793

**The information and recommendations provided are based on the images presented by the referring veterinarian/sonographer. No evaluation can be communicated regarding pathology that was not visible in the image/video clips provided.**

**DATE**

1/26/23

Thank you for this referral. If the clinical or image interpretation does not parallel your findings or if I can be of any further assistance please contact me.



**PATIENT**

Koda Gabriel **Heike Rudolf**, DVM, Dr. med. vet., DipECVDI, DVR  
dr.h.rudorf@gmail.com

**SPECIES**

Canine

**BREED**

Labrador Retriever

**SEX**

Neutered Male

**AGE**

2 Years

**INTERPRETED BY**

Heike Rudolf, DVM,  
Dr. med. Vet.,  
DipECVDI DVR

**HOSPITAL NAME**

Golden Isles AH

**REFERRING VET**

James Hornbuckle

**INVOICE**

20793

**DATE**

1/26/23