



PATIENT PRESENTING CLINICAL SIGNS

Bentley Lynn lethargic, anorexic for one week
 Abnormal PE/Chem/CBC/UA Results: elevated Ca , total bilirubin

SPECIES RADIOGRAPH OF THE THORAX

Canine Lateral thorax/abdomen, VD thorax

BREED RADIOGRAPHIC FINDINGS

Shar Pei The body condition score is 6/9.

SEX The bony structures appear physiological.
 Male Neuter A Leaf shaped (6x5cm), soft tissue mass is present in the right caudo-ventral lung lobe. Multiple, more rounded soft tissue masses of variable diameter are located in the left caudal lobe, mostly dorsally.

AGE The cardiac silhouette occupies 65% of the chest height and 2 intercostal spaces (VHS 8.5). The cranial pulmonary vessels measure 50% of the width of proximal rib 4.

8 Years A kidney shaped soft tissue structure is located in the cranio-dorsal abdomen and appears to be 4x the length of L2 with a depth of 7cm. This structure displaces the descending duodenum ventrally, resulting in a straight duodenum which ascends towards L5.

INTERPRETED BY

Heike Rudolf, DVM,
 Dr. med. Vet.,
 DipECVDDI DVR

RADIOGRAPHIC DIAGNOSIS

- Pulmonary masses
- Hypovolemia
- Duodenal deviation
- Possible renomegaly

HOSPITAL NAME

St. Catherine's Animal Hospital

INTERPRETATION OF THE FINDINGS & FURTHER RECOMMENDATIONS

Hypercalcemia suggests a malignancy. The leaf shaped mass on the right could represent a primary lung tumor and the more rounded masses on the left metastases. However, the changes in the abdomen might be significant and thus the pulmonary masses could represent metastases due to a renal carcinoma.; abdominal ultrasound is necessary. The right sided lung mass is in close proximity to the chest wall and thus accessible for ultrasound guided sampling to identify the tumor type. The small heart may be the result of the hypercalcemia.

REFERRING VET

Dr. Boctor

INVOICE

49751

DATE

1-21-22



PATIENT

Bentley Lynn

SPECIES

Canine

BREED

Shar Pei

SEX

Male Neuter

AGE

8 Years

INTERPRETED BY

Heike Rudorf, DVM,
Dr. med. Vet.,
DipECVDI DVR

HOSPITAL NAME

St. Catherine's Animal
Hospital

REFERRING VET

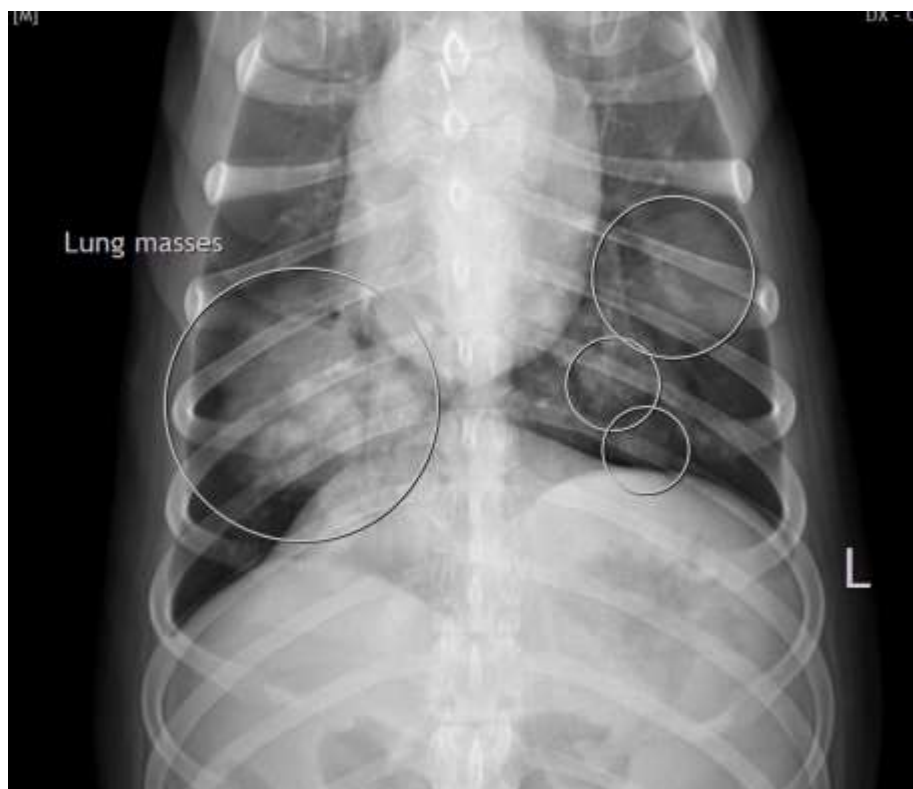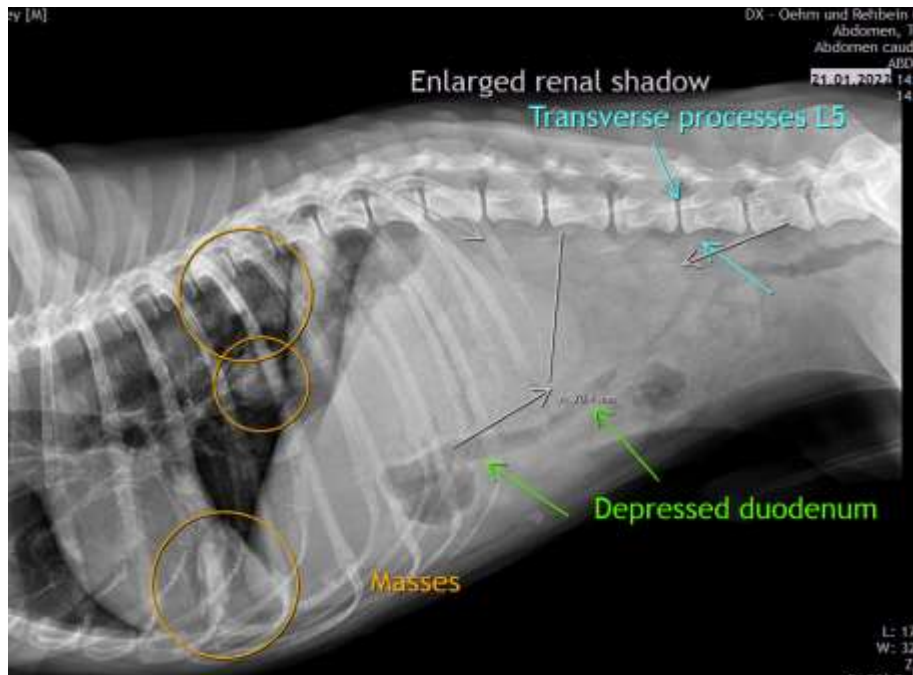
Dr. Boctor

INVOICE

49751

DATE

1-21-22





PATIENT

Bentley Lynn

The information and recommendations provided are based on the images presented by the referring veterinarian/sonographer. No evaluation can be communicated regarding pathology that was not visible in the image/video clips provided.

Thank you for this referral. If the clinical or image interpretation does not parallel your findings or if I can be of any further assistance please contact me.

SPECIES

Canine

Heike Rudolf, DVM, Dr. med. vet., DipECVDI, DVR
Dr.H.Rudorf@gmail.com

BREED

Shar Pei

SEX

Male Neuter

AGE

8 Years

INTERPRETED BY

Heike Rudolf, DVM,
Dr. med. Vet.,
DipECVDI DVR

HOSPITAL NAME

St. Catherine's Animal
Hospital

REFERRING VET

Dr. Boctor

INVOICE

49751

DATE

1-21-22