



PATIENT PRESENTING CLINICAL SIGNS

Teddy Dyck History: intermittent diarrhea for couple months
Abnormal PE/Chem/CBC/UA Results: bloodwork unremarkable

SPECIES RADIOGRAPHIC STUDY OF THE ABDOMEN

Canine The body condition score is 5/9 with little fat in the abdominal cavity.

The bony structures are within normal limits.

BREED

Standard Poodle

The liver is located within the costal arch and the caudo-ventral lobe is pointed.

The spleen appears physiological.

SEX

Male

The stomach contains a moderate amount of food; the diameter and content of the small intestinal loops varies between the views. Colon and rectum contain a moderate amount of fecal matter. The rectum is in close contact with the spine.

AGE

4 Years

Both renal shadows are obscured by intestinal loops. The bladder neck appears to be located in the pelvic canal.

RADIOGRAPHIC DIAGNOSIS

INTERPRETED BY

- Mild ileus, variable location and extent
- Thin dog

Heike Rudolf, DVM,
Dr. med. Vet.,
DipECVDI DVR

INTERPRETATION OF THE FINDINGS & FURTHER RECOMMENDATIONS

The variation of the intestinal diameter in the three views could be due to enteritis or may represent a transient finding. Abdominal ultrasound is recommended to assess gastro-intestinal wall thickens and layering. Repeatedly checking B12 and folate can help identify IBD. Food hypersensitivity or an intermittent enteritis may be present.

HOSPITAL NAME

St. Catharine's AH

TECHNICAL COMMENTS

REFERRING VET

Dr. Boctor

Rotation is present on both lateral views

INVOICE

13512

DATE

1/20/22



PATIENT

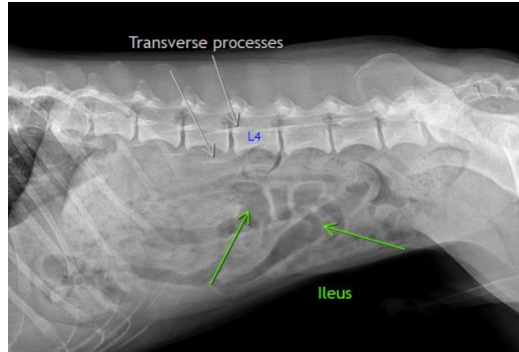
Teddy Dyck

SPECIES

Canine

BREED

Standard Poodle



The information and recommendations provided are based on the images presented by the referring veterinarian/sonographer. No evaluation can be communicated regarding pathology that was not visible in the image/video clips provided.

SEX

Male

Thank you for this referral. If the clinical or image interpretation does not parallel your findings or if I can be of any further assistance please contact me.

AGE

4 Years

Heike Rudolf, DVM, Dr. med. vet., DipECVDI, DVR
dr.h.rudorf@gmail.com

INTERPRETED BY

Heike Rudolf, DVM,
Dr. med. Vet.,
DipECVDI DVR

HOSPITAL NAME

St. Catharine's AH

REFERRING VET

Dr. Boctor

INVOICE

13512

DATE

1/20/22