



## PATIENT

Sunny Hughes

## SPECIES

Canine

## BREED

Mixed

## SEX

Spayed Female

## AGE

6 Years

## WEIGHT

17.5 kg

## INTERPRETED BY

Heike Rudorf, DVM, Dr.  
med. Vet., DipECVDI  
DVR

## IMAGING PERFORMED BY

Dr. Singh

## HOSPITAL NAME

Balmy Beach PH

## REFERRING VET

Dr. Singh

## INVOICE

35202

## DATE

1/2/26

## PRESENTING CLINICAL SIGNS

History: Acute onset of LF limb lameness

Abnormal PE/Chem/CBC/UA Results: Dog was going down the stairs and let out a yelp. no fall or trauma, injury.

## RADIOGRAPHIC STUDY OF THE FORE PAWS

The muscle mass of the antebrachia appear to be symmetrically developed.

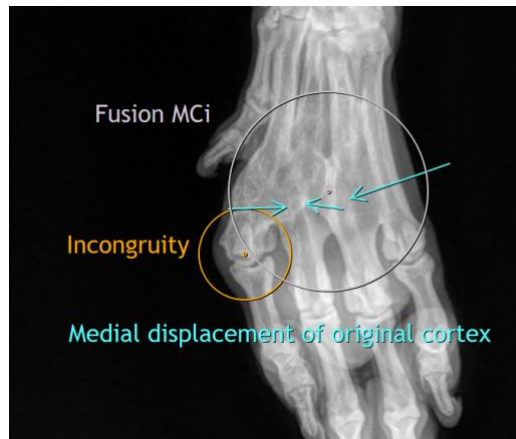L paw: lateral deviation of the digits starts at the mid-portion of the metacarpal (MC). Smooth new bone surrounds this area between MC 2 and 5 and has resulted in fusion. MC 3 and 4 show medial cortical displacement the original cortex is still visible. Distal MC 2 shows rotation in the joint and the smooth new bone affects the lateral aspect as well.

## RADIOGRAPHIC DIAGNOSIS

- Fusion distal MC 2 to 5
- Malunion MC 2 to 4

## INTERPRETATION OF THE FINDINGS & FURTHER RECOMMENDATIONS

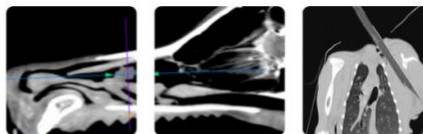
The changes are highly suggestive of old fractures of the distal MC 2-4 with malunion as well as rotational changes MC-phalangeal joint digit 2. It is possible that this has happened in puppyhood due to being stepped on or catching the foot in a door. Due to the cortical malalignment congenital changes are unlikely. It is possible that especially the incongruity of the MC-phalangeal joint 2 has caused the acute onset of pain while misplacing the foot and the pain would be soft tissue (joint capsule, ligaments) in origin. In case conservative treatment does not improve the clinical signs, a CT examination can help identify recent hairline fissures and associated soft tissue damage.



**The information and recommendations provided are based on the images presented by the referring veterinarian/sonographer. No evaluation can be communicated regarding pathology that was not visible in the image/video clips provided.**

Thank you for this referral. If the clinical or image interpretation does not parallel your findings or if I can be of any further assistance, please contact me.

**Heike Rudorf**, DVM, Dr. med. vet., DipECVDI, DVR



**PATIENT**

[info@sonopath.com](mailto:info@sonopath.com)

Sunny Hughes

**SPECIES**

Canine

**BREED**

Mixed

**SEX**

Spayed Female

**AGE**

6 Years

**WEIGHT**

17.5 kg

**INTERPRETED BY**

Heike Rudorf, DVM, Dr.  
med. Vet., DipECVDI  
DVR

**IMAGING  
PERFORMED BY**

Dr. Singh

**HOSPITAL NAME**

Balmy Beach PH

**REFERRING VET**

Dr. Singh

**INVOICE**

35202

**DATE**

1/2/26