



PATIENT

Cosmo Nguyen

SPECIES

Canine

BREED

Husky

SEX

Neutered Male

AGE

11 Years 25 Days

WEIGHT

31.6 kg

INTERPRETED BY

Heike Rudorf, DVM, Dr.
med. Vet., DipECVDD
DVR

IMAGING PERFORMED BY

AMC/LL

HOSPITAL NAME

Green Dog Dental and
Wellness

REFERRING VET

Dr. Hoh

INVOICE

35452

DATE

1/17/26

PRESENTING CLINICAL SIGNS

History: Intermittent limping esp. after P has been lying down for a long period, limping improved with walks. Past medical hx: HX sarcoma, chronic allergies. Current medications: gabapentin, topical duoxo mousse and shampoo

RADIOGRAPHIC STUDY OF THE PELVIS AND STIFLES

The muscles of the hind legs are poorly but symmetrically developed. An oval (2.6x1.5cm) soft tissue opacity is present proximal to the most caudal aspect of the gastrocnemius muscle on the right. A similar opacity (4x1.5 cm) is located in the inguinal region on both lateral hip views.

Cortico-medullary development and differentiation of the long bones are physiological.

Pelvis: the center of both femoral heads is superimposed onto the respective dorsal acetabular edge. Both coxo-femoral joints present smooth osseous margins and congruent joint spaces.

Stifle R: the joint presents with smooth, subchondral bone surfaces. The center of the femoral condyles is in line with the intercondylar eminence of the tibia. The cranial fat pad is not visible, and the caudal fascial plains are well caudally displaced by soft tissue opacity in the joint. A swelling is present on the medial aspect of the joint (buttressing). A small amount of new bone (NB) formation is present on the intercondylar eminence, giving it a mottled appearance on the lateral view. The patella is located centrally in the groove.

Stifle L: the joint presents with smooth, subchondral bone surfaces. The center of the femoral condyles is in line with the intercondylar eminence of the tibia. The cranial fat pad is not visible, and the caudal fascial plains are well caudally displaced by soft tissue opacity in the joint. Medial buttressing is less pronounced than on the right. The intercondylar eminence and the proximal tibia have a mottled appearance on the lateral view. A small amount of NB is present on the lateral condyle. The patella is located centrally in its groove.

RADIOGRAPHIC DIAGNOSIS

Bilateral stifle

- Effusion/fibrosis
- Muscle atrophy

L stifle

- Mottled appearance tibia, mild
- Arthrosis, mild
- Possible lymphadenomegaly

INTERPRETATION OF THE FINDINGS & FURTHER RECOMMENDATIONS

The muscle atrophy is marked; thus, a long-standing process is likely. Soft tissue opacity in the stifle joint can be due to fluid (inflammation, blood, pus) or solid material (fibrosis, soft tissue tumor). Though the small amount of NB formation suggests relative stability of both joints, bilateral cruciate ligament damage is the most likely reason. Alterations in the appearance of trabecular structure can represent artefact due to muscle atrophy or altered radiographic parameters. A true finding can be caused by demineralization due to different weight bearing or infiltrative neoplasm. Depending on the duration of the clinical signs and results of the mass lesions, further tests include clinical re-examination of the stifles in sedation or a CT examination.



PATIENT

Cosmo Nguyen

SPECIES

Canine

BREED

Husky

SEX

Neutered Male

AGE

11 Years 25 Days

WEIGHT

31.6 kg

INTERPRETED BY

Heike Rudolf, DVM, Dr.
med. Vet., DipECVDI
DVR

IMAGING PERFORMED BY

AMC/LL

HOSPITAL NAME

Green Dog Dental and
Wellness

REFERRING VET

Dr. Hoh

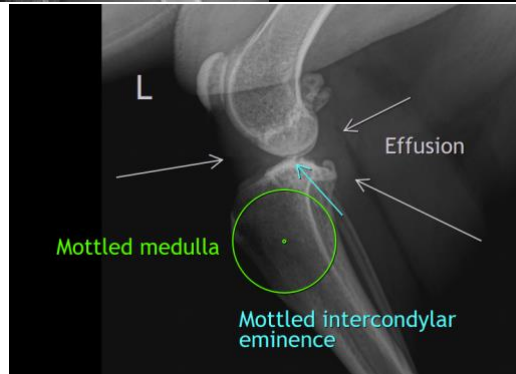
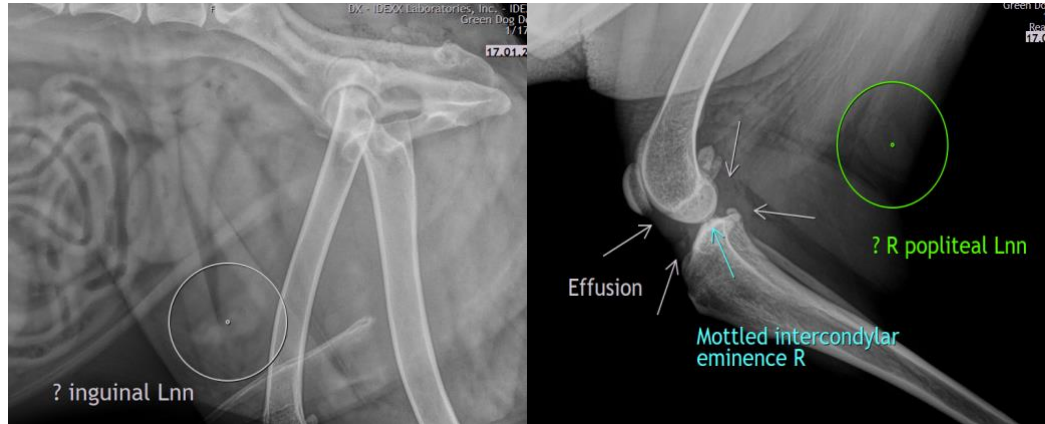
INVOICE

35452

DATE

1/17/26

The soft tissue opacities in the inguinal and popliteal regions may represent lymphadenomegaly or could represent a soft tissue mass of different origin and in the stifle joint an artefact due to superimposition is possible. Palpation is recommended and should a true enlargement be present, samples should be obtained for cytology.



The information and recommendations provided are based on the images presented by the referring veterinarian/sonographer. No evaluation can be communicated regarding pathology that was not visible in the image/video clips provided.

Thank you for this referral. If the clinical or image interpretation does not parallel your findings or if I can be of any further assistance, please contact me.

Heike Rudolf, DVM, Dr. med. vet., DipECVDI, DVR
info@sonopath.com