



PATIENT

Luna Bug Whitton

SPECIES

Feline

BREED

DSH

SEX

Spayed Female

AGE

10 Years 2 Months

WEIGHT

13.40 Pounds

INTERPRETED BY

Heike Rudolf, DVM, Dr.
med. Vet., DipECVDI
DVR

IMAGING PERFORMED BY

Chelsea Lett

HOSPITAL NAME

Elizabeth AH

REFERRING VET

Leon Anderson, DVM

INVOICE

35436

DATE

1/15/26

PRESENTING CLINICAL SIGNS

History: Has developed an intermittent cough. Nothing particular triggers it Seems as though she is trying to catch her breath when it happens.

Abnormal PE/Chem/CBC/UA Results: Heart-based cardiac murmur, loudest on the left side, grade 2/6 systolic Labs pending Mild dried eye discharge

RADIOGRAPHIC STUDY OF THE THORAX

The body condition score is 7/9 with smooth, alternating layers of fat and soft tissue opacity.

The bony structures appear physiological.

The cranial mediastinum is of physiologic size and opacity. The trachea diverges from the thoracic vertebrae, and the carina is located level with T5.

The lung lobes are aerated and extend to the thoracic boundaries. Pulmonary vessels are well outlined to the secondary branches. The bronchial tree is thin walled and tapers towards the periphery.

The cardiac silhouette is tilted cranially which increases the sternal contact. It occupies 65% of the chest height and 2 intercostal spaces. Chamber or outflow tract enlargement is not obvious.

RADIOGRAPHIC DIAGNOSIS

- Reduced outline tertiary vessels

INTERPRETATION OF THE FINDINGS & FURTHER RECOMMENDATIONS

A reduced vascular outline is a non-specific finding and accentuated by the mild obesity. Possible differential diagnoses for a true infiltrate include:

- Edema
- Inflammation (allergic pneumonitis, eosinophilic bronchopneumopathy)
- Infection (bacterial, fungal e.g., candida, viral, parasitic e.g., aelurostrongylus)

Less likely

- Diffuse hemorrhage
- Tumor (e.g., lymphoma)

Fecal samples should be obtained to rule out parasites. Bronchitis can be present without radiographic evidence and thus bronchoscopy with broncho-alveolar lavage is recommended; samples should be submitted for bacteriological and cytological examination. Echocardiography to assess cardiac function and to look for localized thickening caused by HCM is recommended.



PATIENT

Luna Bug Whitton

SPECIES

Feline

BREED

DSH

SEX

Spayed Female

AGE

10 Years 2 Months

WEIGHT

13.40 Pounds

INTERPRETED BY

Heike Rudorf, DVM, Dr.
med. Vet., DipECVDI
DVR

IMAGING PERFORMED BY

Chelsea Lett

HOSPITAL NAME

Elizabeth AH

REFERRING VET

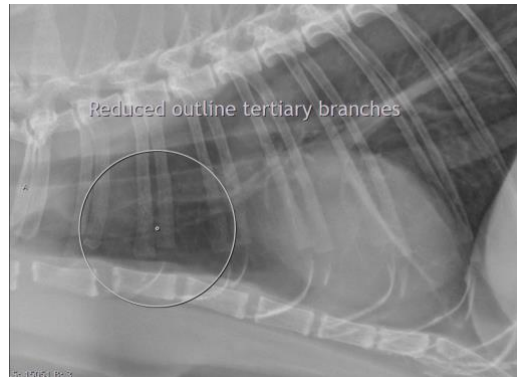
Leon Anderson, DVM

INVOICE

35436

DATE

1/15/26



The information and recommendations provided are based on the images presented by the referring veterinarian/sonographer. No evaluation can be communicated regarding pathology that was not visible in the image/video clips provided.

Thank you for this referral. If the clinical or image interpretation does not parallel your findings or if I can be of any further assistance, please contact me.

Heike Rudorf, DVM, Dr. med. vet., DipECVDI, DVR
info@sonopath.com