



PATIENT PRESENTING CLINICAL SIGNS

Maverick Creel History: Lame left hind, pelvic pain. Breeding cat.

RADIOGRAPHIC STUDY OF THE PELVIS

SPECIES

Feline

Pelvis

Linear and circular gas shadows are present in the left caudo-lateral thigh muscles.

BREED

Bengal

The left obturator foramen appears small and the left wing of the ilium large.

No signs of aggressive osteolysis or bone discontinuity have been identified.

RADIOGRAPHIC DIAGNOSIS

SEX

- Gas in left thigh muscles

Male

INTERPRETATION OF THE FINDINGS & FURTHER RECOMMENDATIONS

AGE

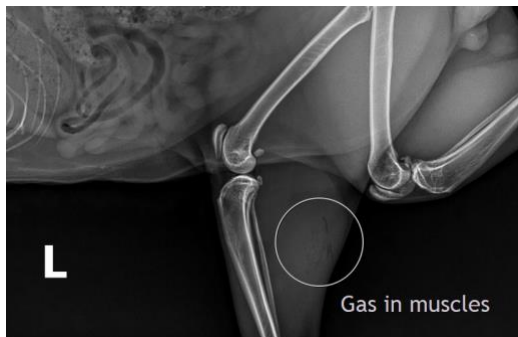
5 Years

Gas in the muscle is most likely the result of a bit or gas forming organisms. Intramuscular injection is a differential diagnosis but would be smaller and more linear. Ultrasound should be performed to identify fluid to obtain a sample for analysis.

The different appearance of both hemipelvis is most likely an artefact due to rotation.

INTERPRETED BY

Heike Rudolf, DVM,
Dr. med. Vet.,
DipECVDDI DVR



HOSPITAL NAME

Pacific Avenue VC

REFERRING VET

Dr. Sid Bruckert-Frisk

The information and recommendations provided are based on the images presented by the referring veterinarian. No evaluation can be communicated regarding pathology that was not visible in the image/video clips provided.

INVOICE

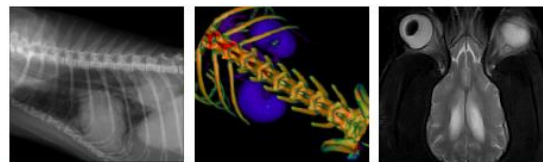
13420

Thank you for this referral. If the clinical or image interpretation does not parallel your findings or if I can be of any further assistance please contact me.

Heike Rudolf, DVM, Dr. med. vet., DipECVDDI, DVR
dr.h.rudorf@gmail.com

DATE

1/14/22



PATIENT

Maverick Creel

SPECIES

Feline

BREED

Bengal

SEX

Male

AGE

5 Years

INTERPRETED BY

Heike Rudorf, DVM,
Dr. med. Vet.,
DipECVDI DVR

HOSPITAL NAME

Pacific Avenue VC

REFERRING VET

Dr. Sid Bruckert-Frisk

INVOICE

13420

DATE

1/14/22