



PATIENT PRESENTING CLINICAL SIGNS

Lily Schuch History: owner noticed coughing started about 1 year ago, occ at first, over the year has increased in frequency.

SPECIES Abnormal PE/Chem/CBC/UA Results: CBC PLT = 71 L NEU = 14.51 H NEU% 80.2 H LYM% 10.9 L MONO% 0.9 L BUN 32.7 H

Feline

RADIOGRAPHIC STUDY OF THE THORAX

BREED

The body condition score is 7-8/9.

DSH

The caudal ribs are more parallel to one another than usual.

SEX

Spayed Female

On VD and DV view a soft tissue/fluid opacity displaces the right cranial lobe away from the rib cage and a thick pleural line separates right cranial from right middle lobe, resulting in rounding of the adjacent lobar edges. On both views the left lung lobes are overinflated causing a mediastinal shift to the right. The edges of the lobar vessels are slightly blurred, and the bronchi are highlighted, especially on the right side.

AGE

11 Years 6 Months

The cardiac silhouette is in contact with the right thoracic wall. The right caudal lobar vessels are tortuous.

RADIOGRAPHIC DIAGNOSIS

- Overexpansion left lung lobes
- Mediastinal shift to the right
- Right cranial thoracic fluid
- Interstitial pattern (R>L)

INTERPRETED BY

Heike Rudolf, DVM,
Dr. med. Vet.,
DipECVDDI DVR

INTERPRETATION OF THE FINDINGS & FURTHER RECOMMENDATIONS

HOSPITAL NAME

Grove VC

The changes are suggestive of obstructive pulmonary disease with overexpansion of the left lobes. The interstitial pattern is most prominent on the right side and could thus represent an artefact due to reduced lung expansion. Possible differential diagnoses for a true infiltrate include:

REFERRING VET

Dr. Luna

- Inflammation (allergic e.g. eosinophilic infiltrate)
- Infection (bacterial, fungal, viral, parasitic)
- Edema
- Hemorrhage
- Tumor (e.g. lymphoma)

INVOICE

13419

In association with pulmonary overinflation, feline asthma appears to be the most likely reason. Collapse of the right middle lobe can be caused by one or a combination of the following:

DATE

1/14/22

- poor collateral ventilation,
- overexpansion of the other lobes,
- a relatively narrow ostium,
- infection/inflammation



PATIENT Further evaluation by means of tracheobronchoscopy with bronchoalveolar lavage should be considered.

Lily Schuch

Unusual is the opacity surrounding the cranial right lung lobe which could represent an exudate or transudate and ultrasound guided aspirates should be obtained. Echocardiography should be considered depending on the result of the fluid aspiration to rule out right sided heart failure.

SPECIES

Feline

Obesity is known to worsen clinical signs of cough and impair lung function; weight control is strongly recommended.

BREED

TECHNICAL COMMENTS

DSH

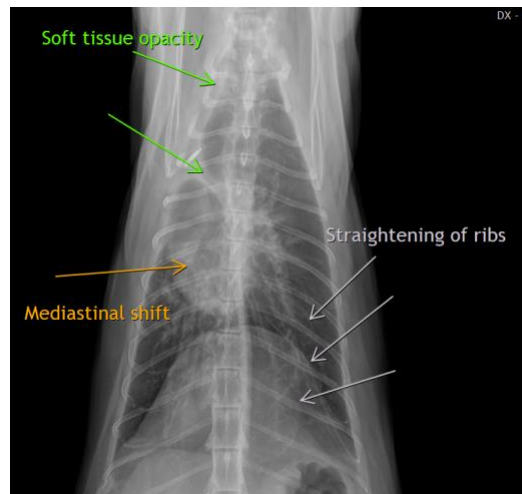
Human fingers in primary beam on DV view.

SEX

Spayed Female

AGE

11 Years 6 Months



INTERPRETED BY

Heike Rudolf, DVM,
Dr. med. Vet.,
DipECVDI DVR

HOSPITAL NAME

Grove VC

The information and recommendations provided are based on the images presented by the referring veterinarian. No evaluation can be communicated regarding pathology that was not visible in the image/video clips provided.

REFERRING VET

Dr. Luna

Thank you for this referral. If the clinical or image interpretation does not parallel your findings or if I can be of any further assistance please contact me.

Heike Rudolf, DVM, Dr. med. vet., DipECVDI, DVR
dr.h.rudorf@gmail.com

INVOICE

13419

DATE

1/14/22



PATIENT

Lily Schuch

SPECIES

Feline

BREED

DSH

SEX

Spayed Female

AGE

11 Years 6 Months

INTERPRETED BY

Heike Rudorf, DVM,
Dr. med. Vet.,
DipECVDI DVR

HOSPITAL NAME

Grove VC

REFERRING VET

Dr. Luna

INVOICE

13419

DATE

1/14/22