


PATIENT PRESENTING CLINICAL SIGNS

Fluff Kenney Reason for Visit: 1. fleas (outdoor pet Nico advantage multi (missed couple doses) -- gave Sun advantage multi on Fluff and other cats in the home. 2. oral odor and noticed less interested in food - dry food 3. coughing - asthma vs hairball

SPECIES Abnormal PE/Chem/CBC/UA Results: No cough on tracheal palpation. Oral Cavity: heavy dental tartar present Skin: Good hair coat, no signs of ectoparasites. ~1 cm SQ mass R lateral thorax
 Feline CV/Respiratory: No murmur/arrhythmia or crackles/wheezing auscultated. Synchronous pulses, normal rate. Normal bronchovesicular sounds.

BREED RADIOGRAPHIC STUDY OF THE THORAX

Maine Coone X 2 orthogonal views.

RADIOGRAPHIC FINDINGS

SEX The body condition score is 7/9 with smooth alternating layers of fat and soft tissue opacity.

Spayed Female Small osteophytes are present on the end plates of T12/13.

AGE The lungs are in contact with the thoracic boundaries and the tips are pointed. The lobar vessels are clearly visible to the secondary branches and appear slightly tortuous in the cranio-ventral lobes.

16 Years 7 Months The cranial mediastinum is of physiological size and opacity. The trachea runs parallel to the thoracic vertebrae and dips at the carina.

INTERPRETED BY The cardiac silhouette occupies 75% of the chest height and 2 intercostal spaces. The heart is rotated cranially and shows a slight increase in sternal contact. On the DV the regions of the atria appear prominent.

Heike Rudolf, DVM,
 Dr. med. Vet.,
 DipECVDI DVR

RADIOGRAPHIC DIAGNOSIS

- HOSPITAL NAME**
- Mild tortuosity of cranial lobar vessels
 - Possible prominence of atria

DPC Vet Hospital

INTERPRETATION OF THE FINDINGS & FURTHER RECOMMENDATIONS

REFERRING VET The cardiovascular changes could be due to the cranial rotation of the heart in older cats.

Dr. White Echocardiography is necessary to rule out HCM if a murmur develops. Bronchitis can be present without radiographic evidence and thus bronchoscopy with broncho-alveolar lavage is necessary to rule out infection and inflammation and may have to be considered if the coughing episodes are more frequent or distressing for the animal. Laryngeal function should also be assessed (during intubation).

INVOICE

34260

DATE

1/14/22



PATIENT

Fluff Kenney

SPECIES

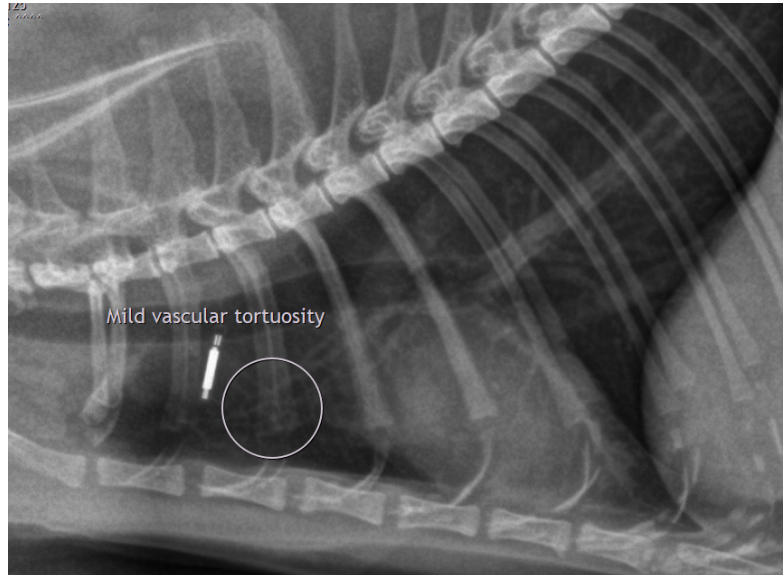
Feline

BREED

Maine Coone X

SEX

Spayed Female



AGE

16 Years 7 Months

The information and recommendations provided are based on the images presented by the referring veterinarian. No evaluation can be communicated regarding pathology that was not visible in the image/video clips provided.

Thank you for this referral. If the clinical or image interpretation does not parallel your findings or if I can be of any further assistance please contact me.

INTERPRETED BY

Heike Rudolf, DVM,
Dr. med. Vet.,
DipECVDI DVR

Heike Rudolf, DVM, Dr. med. vet., DipECVDI, DVR
dr.h.rudorf@gmail.com

HOSPITAL NAME

DPC Vet Hospital

REFERRING VET

Dr. White

INVOICE

34260

DATE

1/14/22