



PATIENT PRESENTING CLINICAL SIGNS

PATIENT Leviticus Johnson **PRESENTING CLINICAL SIGNS** History: got into the trash yesterday and possibly got into pork bones. Had diarrhea and o thought he appeared to straining to urinate. Still e/d ok. No vomit. no bm today. Bar, abd non-painful, normal stool in rectum.

SPECIES RADIOGRAPHIC STUDY OF THE ABDOMEN

SPECIES Canine The body condition score is 5-6/9 with smooth alternating layers of fat and soft tissue opacity.

BREED The bony structures are within normal limits.

BREED Pitbull The abdominal detail is reasonable and in line with the given age; diaphragm and abdominal wall are intact.

SEX The liver is located within the costal arch and the caudo-ventral lobe is pointed.

SEX Neutered Male The head of the spleen appears physiological.

AGE 12 Months The stomach is moderately distended by food. Multiple calcified structures with smooth edges are evident in the ventral intestinal loops; distribution and size of the small intestinal loops appear physiological. The amount of gas varies in the four views. Colon and rectum contain a moderate amount of fecal matter.

INTERPRETED BY The left renal shadow has a physiological size, shape and opacity; the right is obscured by intestinal loops. The head of the fluid filled bladder is just visible at the edge of the lateral views.

INTERPRETED BY Heike Rudolf, DVM, Dr. med. Vet., DipECVDI DVR The sublumbar region appears physiological.

RADIOGRAPHIC DIAGNOSIS

- Small bony structures in small intestine

HOSPITAL NAME

The Pet Hospital of Stratford

INTERPRETATION OF THE FINDINGS & FURTHER RECOMMENDATIONS

The dog has indeed eaten bony structures but they seem to be moving through the small intestine unimpeded. The dog should be observed carefully, in case a gravel sign appears at the ileo-ceco-colic junction. Conservative treatment, including an i.v. drip can speed up the movement and ensure that mucosal damage is not sustained. Alternatively, the amount of oral intake of liquid can be increased.

REFERRING VET

20580

INVOICE

20580

DATE

1/13/23

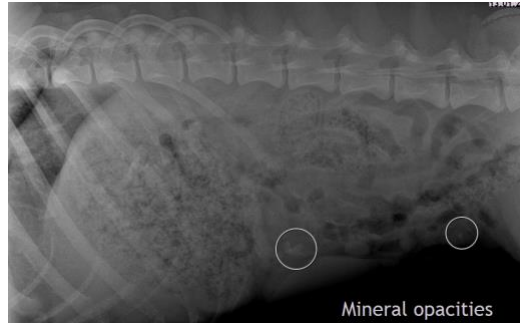


PATIENT

Leviticus Johnson

SPECIES

Canine



BREED

Pitbull

The information and recommendations provided are based on the images presented by the referring veterinarian/sonographer. No evaluation can be communicated regarding pathology that was not visible in the image/video clips provided.

SEX

Neutered Male

Thank you for this referral. If the clinical or image interpretation does not parallel your findings or if I can be of any further assistance please contact me.

Heike Rudorf, DVM, Dr. med. vet., DipECVDDI, DVR
dr.h.rudorf@gmail.com

AGE

12 Months

INTERPRETED BY

Heike Rudorf, DVM,
Dr. med. Vet.,
DipECVDDI DVR

HOSPITAL NAME

The Pet Hospital of
Stratford

REFERRING VET

20580

INVOICE

20580

DATE

1/13/23