



PATIENT	PRESENTING CLINICAL SIGNS
Poochie Hertbertson	Poochie won't eat, he threw up twice this morning and more over the week. Poochie has been laying around. He is not even interested in food. They live in the country so he eats all sorts of things. He got hold of a chap-stick tube last week. They do not know if he ingested anything. His stool was soft this morning and is continually getting worse.
SPECIES	Abnormal PE/Chem/CBC/UA Results: UNCOMFORTABLE TO ABDOMINAL PALPATION
Canine	
BREED	RADIOGRAPH OF THE ABDOMEN
Labradoodle	2x RLR, 2x LLR, 2x VD
SEX	RADIOGRAPHIC FINDINGS
Neutered Male	The body condition score is 5/9 with little abdominal fat.
AGE	The bony structures are within normal limits.
1 Year, 5 Months	The liver is located within the costal arch and the caudo-ventral lobe is pointed.
INTERPRETED BY	The spleen appears physiological.
Heike Rudolf, DVM, Dr. med. Vet., DipECVDI DVR	The stomach contains some air which enters the duodenum readily in left lateral recumbency.
HOSPITAL NAME	The small intestinal loops have a physiological distribution and size. Colon and rectum contain a moderate amount of formed fecal matter. The caecum is filled with feces.
Elizabeth Animal Hospital	Both renal shadows appear to have a physiological size, the intraabdominal bladder contains a small amount of homogeneous fluid opacity.
REFERRING VET	The sublumbar region appears physiological.
Kim Allyn, DVM	RADIOGRAPHIC DIAGNOSIS
INVOICE	<ul style="list-style-type: none"> I can see no explanation for the clinical signs
49560	INTERPRETATION OF THE FINDINGS & FURTHER RECOMMENDATIONS
DATE	Full biochemistry (including pancreatic lipase to rule out pancreatitis) and hematology should be obtained if it has not already been done. Abdominal ultrasound will help asses gastro-intestinal wall thickens and layering as well as identifying lymph node enlargement (e.g. lymphadenitis). There may be a problem with feces passing from the cecum into the ascending colon thus another VD is recommended to compare with these radiographs. Supportive treatment is recommended to reduce pain and nausea.
1-13-22	



PATIENT

Poochie Hertbertson

SPECIES

Canine

BREED

Labradoodle

SEX

Neutered Male

AGE

1 Year, 5 Months

INTERPRETED BY

Heike Rudorf, DVM,
Dr. med. Vet.,
DipECVDDI DVR

HOSPITAL NAME

Elizabeth Animal
Hospital

REFERRING VET

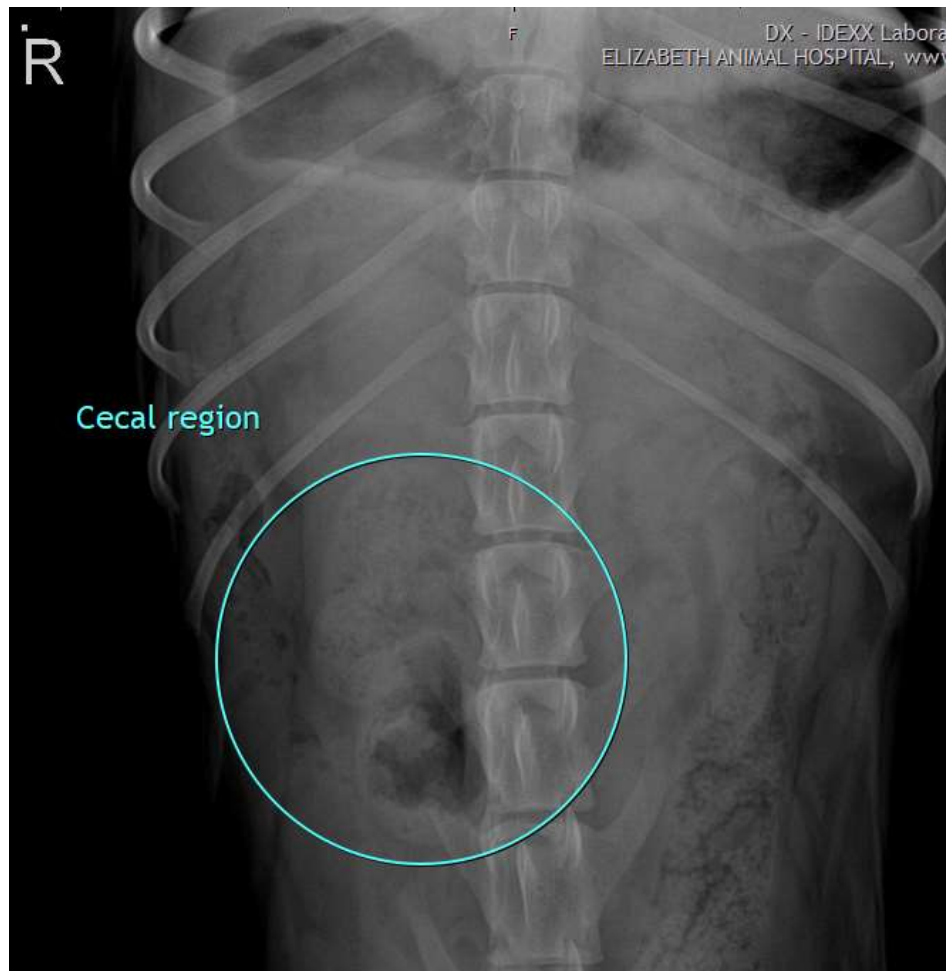
Kim Allyn, DVM

INVOICE

49560

DATE

1-13-22



The information and recommendations provided are based on the images presented by the referring veterinarian. No evaluation can be communicated regarding pathology that was not visible in the image/video clips provided.

Thank you for this referral. If the clinical or image interpretation does not parallel your findings or if I can be of any further assistance please contact me.

Heike Rudorf, DVM, Dr. med. vet., DipECVDDI, DVR
Dr.H.Rudorf@gmail.com