



PATIENT

Hunter Duliba

PRESENTING CLINICAL SIGNS

Ongoing limp on RFL. DWB RFL but no anomalies on limb except possible reaction on deep palpation of greater tubercle.

SPECIES

Canine

RADIOGRAPH OF C-SPINE AND SHOULDERS

Lateral C-spine, VD C-spine including shoulders and elbows, 2x lateral R scapula to elbow

BREED

Pitbull Mix

RADIOGRAPHIC FINDINGS

C-Spine

No signs of aggressive osteolysis have been identified.

SEX

Neutered Male

The surrounding muscles and fat layers appear physiological.

Number and shape of the vertebrae are physiological. They are well mineralized and have smooth surfaces.

AGE

8 Years

The facet joints appear to be congruent.

The C5/6 disc space appears to be slightly reduced.

INTERPRETED BY

Heike Rudolf, DVM,
Dr. med. Vet.,
DipECVDDVR

Shoulders

The muscles of the upper arm appear to be symmetrically developed.

The bones are well mineralized and have smooth, continuous surfaces. Cortical-medullary development and differentiation of the long bones are physiological.

HOSPITAL NAME

River Valley
Veterinary Wellness
Clinic

The shoulder joint appears congruent with even subchondral bone surfaces. On one lateral view a mineral opacity appears to be superimposed onto the greater tubercle but is no longer evident on the view with the leg extended further cranially.

RADIOGRAPHIC DIAGNOSIS

REFERRING VET

Dr. Jennifer Stelfox

- Possible reduction of C5/6-disc space.

INTERPRETATION OF THE FINDINGS & FURTHER RECOMMENDATIONS

INVOICE

49558

Accurate positioning of the spine is difficult even under G.A. and cord compression can only be identified with myelography or in cross sectional imaging. Depending on the severity of the clinical signs, contrast CT or MRI will be necessary in case an extruded disc needs to be removed. The brachial plexus should be examined at the same time to rule out neural pathology. The shoulder joints can also be included to identify if tendinopathy or myositis is present.

DATE

1-13-22



PATIENT

Hunter Duliba

TECHNICAL COMMENTS

In animals weighing more than 10 kg, I recommend using a grid for spinal and shoulder radiographs.

SPECIES

Canine

BREED

Pitbull Mix

SEX

Neutered Male

AGE

8 Years

INTERPRETED BY

Heike Rudorf, DVM,
Dr. med. Vet.,
DipECVDI DVR

HOSPITAL NAME

River Valley
Veterinary Wellness
Clinic

REFERRING VET

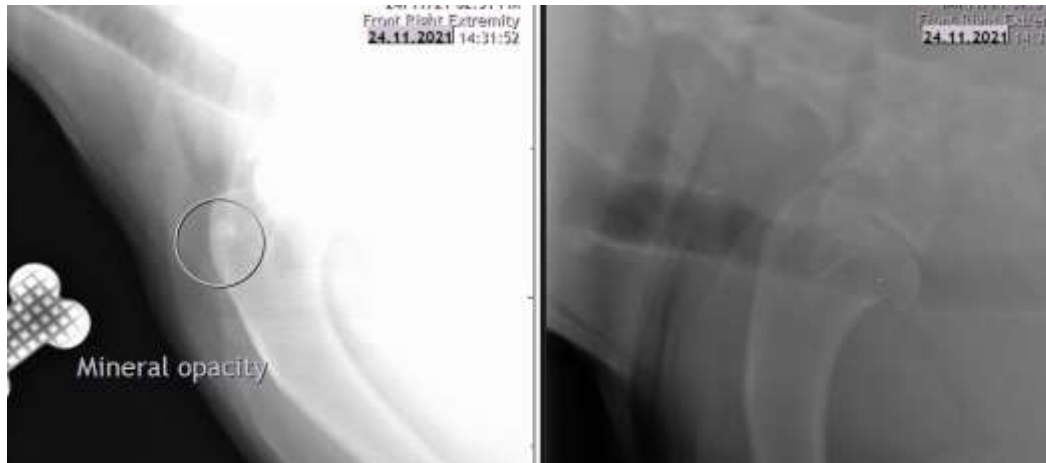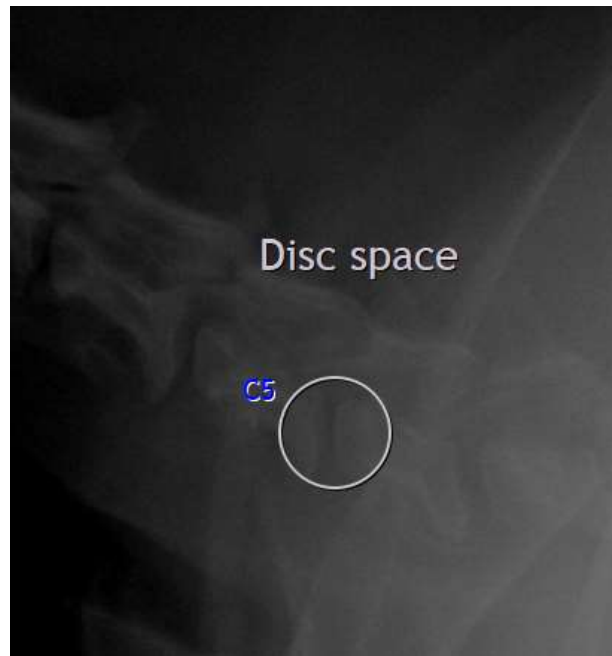
Dr. Jennifer Stelfox

INVOICE

49558

DATE

1-13-22





PATIENT

Hunter Duliba

The information and recommendations provided are based on the images presented by the referring veterinarian. No evaluation can be communicated regarding pathology that was not visible in the image/video clips provided.

SPECIES

Canine

Thank you for this referral. If the clinical or image interpretation does not parallel your findings or if I can be of any further assistance please contact me.

BREED

Pitbull Mix

Heike Rudorf, DVM, Dr. med. vet., DipECVDI, DVR
Dr.H.Rudorf@gmail.com

SEX

Neutered Male

AGE

8 Years

INTERPRETED BY

Heike Rudorf, DVM,
Dr. med. Vet.,
DipECVDI DVR

HOSPITAL NAME

River Valley
Veterinary Wellness
Clinic

REFERRING VET

Dr. Jennifer Stelfox

INVOICE

49558

DATE

1-13-22