



**PATIENT PRESENTING CLINICAL SIGNS**

**Mia Meow Stevens** History: Owner accidentally sat on cat ~ 2 weeks ago. Non weight bearing on left hind immediately after but then toe-touching. Was given onsiar and gabapentin - o initially though improving but after stopping medications noted p still painful and not using leg.

**SPECIES RADIOGRAPHIC STUDY OF THE PELVIS**

**Feline** The muscle mass on the left hind leg is markedly reduced.

Skeletal immaturity compatible with the given age is noted.

**BREED**

**DSH** On the lateral view the left hip joint is irregularly widened. On the VD view the femoral head epiphysis is in a physiological position. The femoral neck is slightly cranially displaced with a small, rounded tip. A smooth, triangular fragment extends cranially over the level of the joint space. A growth plate is not clearly visible.

**SEX**

**RADIOGRAPHIC DIAGNOSIS**

**Intact Female** Left

**AGE**

- Fracture femoral neck
- Muscle atrophy, severe

**5 Months INTERPRETATION OF THE FINDINGS & FURTHER RECOMMENDATIONS**

The femoral neck fracture most likely represents a Salter Harris fracture and further imaging should be performed (preferably CT). On these radiographs the impression is that of a marked narrowing of the femoral fragment which makes surgical stabilization with a pin difficult. Femoral head/neck resection may be the better option.

**INTERPRETED BY**

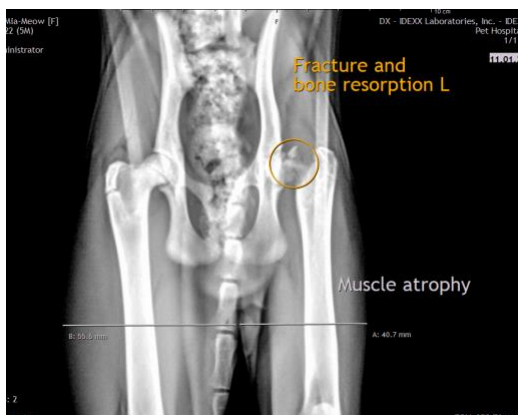
**Heike Rudorf, DVM, Dr. med. Vet., DipECVDI DVR**

**HOSPITAL NAME**

**The Pet Hospital of Stratford**

**REFERRING VET**

**Dr. Claudia Giuliani**



**INVOICE** The information and recommendations provided are based on the images presented by the referring veterinarian/sonographer. No evaluation can be communicated regarding pathology that was not visible in the image/video clips provided.  
20570

**DATE**

1/11/23

Thank you for this referral. If the clinical or image interpretation does not parallel your findings or if



**PATIENT** I can be of any further assistance please contact me.

Mia Meow Stevens **Heike Rudolf**, DVM, Dr. med. vet., DipECVDI, DVR  
dr.h.rudorf@gmail.com

**SPECIES**

Feline

**BREED**

DSH

**SEX**

Intact Female

**AGE**

5 Months

**INTERPRETED BY**

Heike Rudolf, DVM,  
Dr. med. Vet.,  
DipECVDI DVR

**HOSPITAL NAME**

The Pet Hospital of  
Stratford

**REFERRING VET**

Dr. Claudia Giuliani

**INVOICE**

20570

**DATE**

1/11/23