



PATIENT PRESENTING CLINICAL SIGNS

Dodger Reibel History: History of URI's, congestion, wheezy at home, raspy respiration, coughs on occasion, nasal and ocular discharge

SPECIES Abnormal PE/Chem/CBC/UA Results: Slight Polycythemia Borderline Hyperkalemia

Feline RADIOGRAPHIC STUDY OF THE THORAX

The body condition score is 8/9 with smooth alternating layers of fat and soft tissue opacity.

BREED

The bony structures appear physiological.

DSH

The lungs are in contact with the thoracic boundaries and the tips are pointed. Tramlines and doughnuts are present throughout the lung fields and some bronchi hardly taper before branching indicating bronchiectasis.

SEX

Neutered Male

The cranial mediastinum is of physiological size and opacity. The trachea diverges from the thoracic vertebrae and is of homogeneous height.

AGE

10 Years 4 Months

The cardiac silhouette occupies 75%; cranial and caudal borders are obscured by lung pathology. On the VD view a mediastinal shift to the right is present with close contact between heart and rib cage.

RADIOGRAPHIC DIAGNOSIS

INTERPRETED BY

- Peribronchial infiltrate

Heike Rudolf, DVM,
Dr. med. Vet.,
DipECVDDI DVR

INTERPRETATION OF THE FINDINGS & FURTHER RECOMMENDATIONS

HOSPITAL NAME

Long Valley AH

The lung pattern indicates bronchitis. Primary inflammatory, non-infectious causes (e.g. neutrophilic, eosinophilic, allergic), as well as infectious causes (bacterial, viral, parasitic) need to be considered. Bronchoscopy including BAL is necessary for a definitive diagnosis. The mediastinal shift is most likely caused by poor lung re-inflation of the lungs, poor collateral ventilation, overexpansion of the other lobes, a relatively narrow ostium, or infection/inflammation.

REFERRING VET

Dr. Earl

Obesity is known to worsen clinical signs of cough and impair lung function; weight control is strongly recommended. Should the clinical signs persist despite a histological diagnosis and treatment, the nasal passages should be examined.

INVOICE

13072

DATE

9/14/21



PATIENT

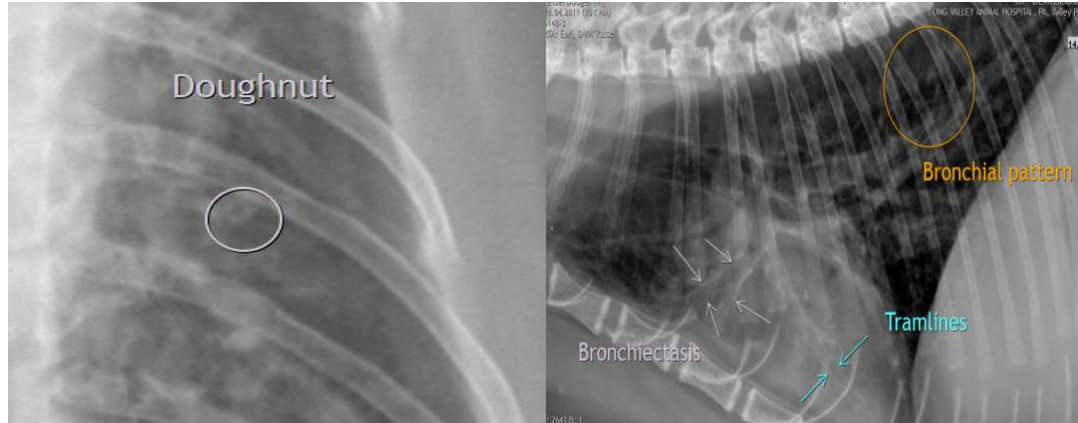
Dodger Reibel

SPECIES

Feline

BREED

DSH



SEX

Neutered Male

AGE

10 Years 4 Months

The information and recommendations provided are based on the images presented by the referring veterinarian. No evaluation can be communicated regarding pathology that was not visible in the image/video clips provided.

Thank you for this referral. If the clinical or image interpretation does not parallel your findings or if I can be of any further assistance please contact me.

Heike Rudorf, DVM, Dr. med. vet., DipECVDI, DVR
dr.h.rudorf@gmail.com

INTERPRETED BY

Heike Rudorf, DVM,
Dr. med. Vet.,
DipECVDI DVR

HOSPITAL NAME

Long Valley AH

REFERRING VET

Dr. Earl

INVOICE

13072

DATE

9/14/21