

DATE PRESENTING CLINICAL SIGNS

8/14/21

Elevated liver enzymes, FIV +, Mast Cell skin mass removed.

INTERPRETED BY CYTOLOGY SUBMISSION

L.D. McGill, DVM,
Ph.D, DACVP

U/S Guided FNA: Liver

OBSERVATIONS

PATIENT

Gus Doyle

Liver: Submitted are 2 excellent videos of moderate cellular collections from the liver in Gus Gus. There is a mixture of cells. Hepatocytes demonstrate vacuolization of a mild to moderate degree. This vacuolization appears to be lipid. The hepatocytes are associated with scattered neutrophils and good numbers of lymphocytes. Most of the lymphocytes are small and mature. There are reactive lymphocytes in the collection. Malignant characteristics are not identified.

SPECIES

Feline

INTERPRETATION OF THE FINDINGS & FURTHER RECOMMENDATIONS

Liver - Moderate feline fatty liver with moderate lymphocytic infiltration suggesting inflammation.

BREED

DSH

COMMENTS

SEX

Male Neutered

The changes support a lymphocytic inflammatory infiltration with secondary feline fatty liver syndrome. This is likely secondary to inflammation in other organs such as the intestine or pancreas. I cannot identify malignancy or sepsis in Gus. The lymphocytes may suggest early lymphoma but this is not confirmed with the cells we can see. The lymphocytic infiltration is not effacing the cellularity. If it is early lymphoma, then it is a small to intermediate cell type which will require biopsies to confirm. With the cells I am seeing, this is most likely a lymphocytic hepatopathy with secondary lipidosis. Treatment for inflammation and evaluation of other organs for a potential reaction in other organs may be in order.

AGE

12y

WEIGHT

10 lbs

HOSPITAL NAME

Franklin Lakes Animal
Hospital

REFERRING VET

Dr. Onesios

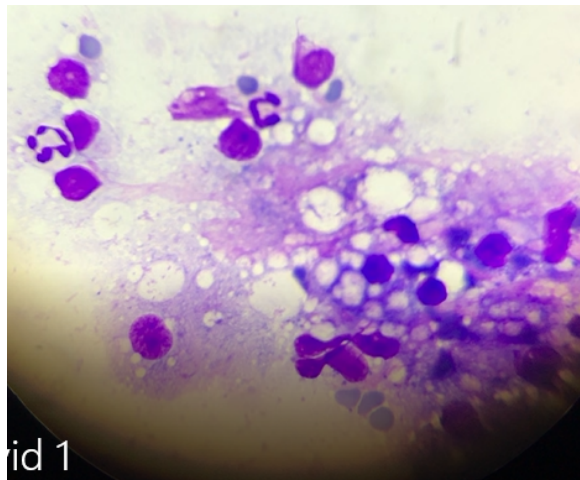
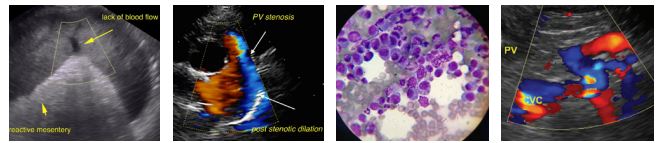


Image shows lymphocytes and neutrophils with lipidotic hepatocytes in the lower right corner from the liver in Gus

INVOICE NUMBER

9075



DATE

8/14/21

INTERPRETED BY

L.D. McGill, DVM,
Ph.D, DACVP

The information and recommendations provided are based on the images presented by the referring veterinarian. No evaluation can be communicated regarding pathology that was not visible in the image/video clips provided.

Thank you for this referral. If the clinical or image interpretation does not parallel your findings or if I can be of any further assistance please contact me.

PATIENT

Gus Doyle

L.D. McGill, DVM, Ph.D., DACVP

8288 Top of the World Drive
Cottonwood Heights, UT 84121
ldmcgill.vetpath@gmail.com
cell: 801-865-1220

SPECIES

Feline

BREED

DSH

SEX

Male Neutered

AGE

12y

WEIGHT

10 lbs

HOSPITAL NAME

Franklin Lakes Animal
Hospital

REFERRING VET

Dr. Onesios

INVOICE NUMBER

9075