



## PATIENT

Murphy Dykes

## SPECIES

Canine

## BREED

Bulldog Mix

## SEX

MN

## AGE

5 years

## WEIGHT

5 years 9 months

## INTERPRETED BY

Greg Kuhlman, DVM,  
DACVIM (SAIM)

## IMAGING PERFORMED BY

Dr. Rivera

## HOSPITAL NAME

DPC Veterinary  
Hospital

## REFERRING VET

Dr. Rivera

## INVOICE

12120

## DATE

6/9/2026

## PRESENTING CLINICAL SIGNS

Murphy presented today for a diagnostic abdominal ultrasound. Murphy was previously evaluated on June 4th for a demonstration of our new ultrasound machine, during which a suspected right adrenal mass was identified incidentally. At this time, the patient is not exhibiting clinical signs consistent with hyperadrenocorticism.

## ULTRASONOGRAPHIC EXAMINATION OF THE ABDOMEN

### Urinary System

The bladder is moderately distended with anechoic urine. No uroliths are seen. The bladder wall is normal in appearance and thickness. No masses are seen.

Prostate is normal in size (8.5 mm in width), echotexture, and echogenicity for a neutered male.

The left kidney presents normal size with normal shape and architecture. Normal corticomedullary distinction. No pyelectasia, ureteral dilation or nephrolithiasis. The left kidney measured 4.8 cm in length.

The right kidney presents normal size with normal shape and architecture. Normal corticomedullary distinction. No pyelectasia, ureteral dilation or nephrolithiasis. The right kidney measured 4.5 cm in length.

### Adrenal Glands

The left adrenal gland presents normal shape and homogenous parenchyma. The phrenic vasculature is unremarkable. The cranial pole measures 5.3 mm and the caudal pole measures 6.3 mm.

A nodule/mass is noted in the cranial pole of the right adrenal gland and measures 2.1 cm in width and is isoechoic to the remainder of the adrenal gland. caudal pole measures 7.8 mm in width.

### Spleen

The spleen is normal in size, shape, margination and echogenicity. No masses are seen.

### Liver

Liver is subjectively enlarged (swollen contour) without disruption of architecture. It has a normal homogenous echotexture. Parenchyma is diffusely hyperechoic characterized by less prominent than normal portal vein walls and increased echogenicity relative to the spleen and falciform fat. No focal lesions are observed. Visible vasculature and biliary tree appear normal without distension or congestion.

The gallbladder presents normal size with anechoic contents. Normal gallbladder wall. No evidence of bile duct distention or obstruction.

### Gastrointestinal

The stomach and intestines have normal wall layering and thickness. Colon contains normal contents with normal wall thickness.

### Pancreas



## PATIENT

Murphy Dykes

## SPECIES

Canine

## BREED

Bulldog Mix

## SEX

MN

## AGE

5 years

## WEIGHT

5 years 9 months

## INTERPRETED BY

Greg Kuhlman, DVM,  
DACVIM (SAIM)

## IMAGING PERFORMED BY

Dr. Rivera

## HOSPITAL NAME

DPC Veterinary  
Hospital

## REFERRING VET

Dr. Rivera

## INVOICE

12120

## DATE

6/9/2026

The visible pancreas is normal in size with normal echogenic parenchyma and surrounded by normal peri-pancreatic mesentery.

### *Free Abdomen*

There are no enlarged abdominal lymph nodes seen on this exam. No free abdominal fluid is seen.

## ULTRASONOGRAPHIC FINDINGS

- Hyperechoic hepatomegaly – This appearance is non-specific and most consistent with a benign steroid (endocrine) or vacuolar hepatopathy or reactive, idiopathic hepatopathy, possibly caused by hyperadrenocorticism, hypertriglyceridemia, hypothyroidism, pancreatic or GI disease. Inflammatory and/or infiltrative disease (such as round cell neoplasia) are also possible but considered less likely.
- Adrenal nodule in the cranial pole of the right adrenal gland – Differentials include primary adrenal cortical adenoma or adenocarcinoma, pheochromocytoma, myelolipoma, adrenal hyperplasia secondary to pituitary disease or metastatic disease. Ultrasound alone cannot differentiate between functional and non-functional nodules and/or between benign and malignant disease. Small nodules without other evidence of abdominal disease (to suggest metastatic disease) and/or clinical signs (to suggest adrenal disease) are most often incidental and should be monitored.

## INTERPRETATION OF THE FINDINGS & FURTHER RECOMMENDATIONS

Given the presence of the mass at the cranial pole of the right adrenal gland, if the patient is diagnosed with hyperadrenocorticism, suspected to be adrenal dependent hyperadrenocorticism, however the contralateral adrenal gland is normal in size as is the caudal pole of the right adrenal gland. If there was excessive cortisol production, I would expect some atrophy of the contralateral adrenal gland, as well as the caudal pole of the right adrenal gland.

In this patient's case it is reported that they are showing clinical signs consistent with hyperadrenocorticism. Recommend a low dose dexamethasone suppression test to further evaluate for this disease. If hyperadrenocorticism is ruled out, consider screening patient for other diseases which may be causing a secondary benign vacuolar hepatopathy. It would be prudent to obtain a systemic blood pressure to determine if hypertension is present as well as submitting a urine metanephrine test to either IDEXX or Zoetis to screen the patient for the possibility of a pheochromocytoma.

If possible, a presurgical planning contrast CT scan of the abdomen would be recommended to fully characterize the mass in the area of the right adrenal gland, and to determine if surgical resection is feasible as a right adrenalectomy would be recommended if surgery is pursued.

Prior to surgery, recommend imaging of the chest to screen the patient for pulmonary metastatic disease.

Being the size of the mass being over 2.0 cm in size, there is some concern that it may potentially be a malignant carcinoma. However, given that pheochromocytoma is considered possible, a fine needle aspirate of the adrenal mass is not recommended. If adrenalectomy is performed, recommend submission for histopathology to determine if malignancy is present.



## PATIENT

Murphy Dykes

## SPECIES

Canine

## BREED

Bulldog Mix

## SEX

MN

## AGE

5 years

## WEIGHT

5 years 9 months

## INTERPRETED BY

Greg Kuhlman, DVM,  
DACVIM (SAIM)

## IMAGING PERFORMED BY

Dr. Rivera

## HOSPITAL NAME

DPC Veterinary  
Hospital

## REFERRING VET

Dr. Rivera

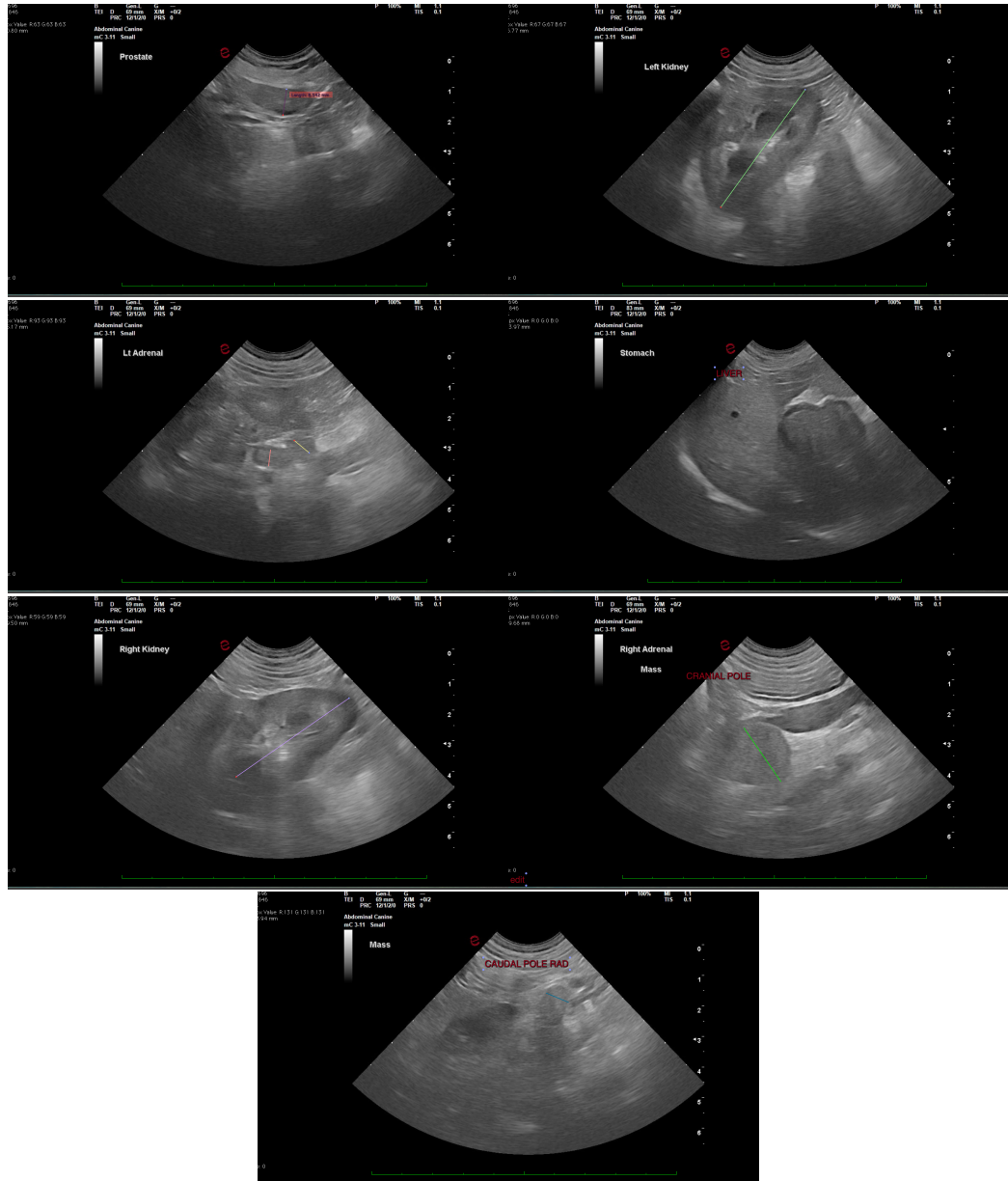
## INVOICE

12120

## DATE

6/9/2026

If surgery is not an option for this patient, then I recommend rechecking this mass every 2-3 months via ultrasound to determine how rapidly it is increasing in size.



The information and recommendations provided are based on the images presented by the referring veterinarian/sonographer. No evaluation can be communicated regarding pathology that was not visible in the image/video clips provided.

Thank you for this referral. If the clinical or image interpretation does not parallel your findings or if I can be of any further assistance, please contact me.



## PATIENT

Murphy Dykes

Greg Kuhlman, DVM, DACVIM (SAIM)

Veterinary Internal Medicine Specialist

[info@SonoPath.com](mailto:info@SonoPath.com)

## SPECIES

Canine

## BREED

Bulldog Mix

## SEX

MN

## AGE

5 years

## WEIGHT

5 years 9 months

## INTERPRETED BY

Greg Kuhlman, DVM,  
DACVIM (SAIM)

## IMAGING PERFORMED BY

Dr. Rivera

## HOSPITAL NAME

DPC Veterinary  
Hospital

## REFERRING VET

Dr. Rivera

## INVOICE

12120

## DATE

6/9/2026